

## Oral cancer: Current and future diagnostic techniques

**CRISPAN SCULLY**, CBE, PhD, MD, MDS, MRCS, FDSRCPS, FFDRCSI, FDSRCS, FDSRCSE, FRCPATH, FMEDSCI, FHEA, FUCL, DSC, DCHD, DMED(HC), **JOSÉ V. BAGAN**, DDS, PhD, MD, **COLIN HOPPER**, MD, FRCS(Ed), FDSRCS & **JOEL B. EPSTEIN**, DMD, MSD, FRCD(C), FDSRCSE

**ABSTRACT:** Oral cancer is among the 10 most common cancers worldwide, and is especially seen in disadvantaged elderly males. Early detection and prompt treatment offer the best chance for cure. As patient awareness regarding the danger of oral cancer increases, the demand for “screening” is expected to increase. The signs and symptoms of oral cancer often resemble less serious conditions more commonly found and similarly usually presenting as a lump, red or white patch or ulcer. If any such lesion does not heal within 3 weeks, a malignancy or some other serious disorder must be excluded and a biopsy may be indicated. Dental health care workers have a duty to detect benign and potentially malignant oral lesions such as oral cancer and are generally the best trained health care professionals in this field. Prompt referral to an appropriate specialist allows for the best management but, if this is not feasible, the dental practitioner should take the biopsy which should be sent to an oral/head and neck pathologist for histological evaluation. (*Am J Dent* 2008;21:199-209).

**CLINICAL SIGNIFICANCE:** Early detection and prompt treatment offer the best hope to the patient with oral cancer, providing the best chance of cure. As patient awareness regarding the danger of oral cancer increases, the demand for “screening” is expected to increase.

✉: Prof. Crispian Scully, UCL Eastman Dental Institute, 256 Gray’s Inn Road, University College London, London WC1X 8LD, United Kingdom. E-✉: [crispian.scully@eastman.ucl.ac.uk](mailto:crispian.scully@eastman.ucl.ac.uk)

### Introduction

Most cancers of the oral cavity are oral squamous cell carcinomas (OSCC), and tobacco, alcohol and betel use the main risk factors for these and many potentially malignant lesions (PML)<sup>1,2</sup> (Fig. 1). The main high risk groups are older adult males who use tobacco and alcohol.

It is expected that early diagnosis of PML can reduce mortality.<sup>3,4</sup> Early diagnosis of OSCC can speed proceeding to treatment and can improve the prognosis.<sup>5</sup> This requires patients to seek an oral and dental examination at an early stage.

Conventional oral examination (COE) is the standard method of revealing PML and OSCC, confirming the clinical suspicion by biopsy and histopathological examination. Histopathology has for many years been the gold standard in the diagnosis of OSCC; however, it is a rather slow process, requiring several days to fix, embed and stain the biopsy specimen before results can be available. It is subject to interpretation of pathologists, and although it can detect cellular changes, it can only detect molecular changes if special techniques are employed.

This review outlines the signs and symptoms of oral cancer and potentially malignant lesions, which often resemble less serious conditions more commonly found in the mouth and discusses the available and developing adjuncts for detection and diagnosis of oral cancer. All such techniques require more multicenter cross-sectional/longitudinal controlled trials in high risk patients and low risk populations with histologic outcomes.

### Potentially malignant oral lesions

OSCC may be preceded by clinically evident PMLs, particularly erythroplakia (erythroplasia) (Fig. 2) and some leukoplakias (Fig. 3). Erythroplasia is rare, and presents as a velvety red plaque. At least 85% of cases show frank malignancy or severe dysplasia and carcinomas are seen 17 times more frequently in erythroplakia than in leukoplakia even

though leukoplakias are far more common. Leukoplakia is the most common potentially malignant oral lesion and may also be potentially malignant, transformation ranging from 3-33% over 10 years.<sup>1,2,6,7</sup> The higher transformation rates are seen particularly where there are red lesions admixed, as in speckled leukoplakia, and in proliferative verrucous leukoplakia (Fig. 4); sublingual leukoplakia (Fig. 5); candidal leukoplakia (Fig. 6); and syphilitic leukoplakia (exceptionally rare now). Not all leukoplakias are potentially malignant; for example, hairy leukoplakia seen mainly in immunosuppressed people, has no known malignant potential. The other potentially malignant lesions or conditions may include actinic cheilitis, oral submucous fibrosis and some lichen planus (Table 1). However, most other oral white lesions, such as homogeneous leukoplakias, have very low potential for malignant transformation.

The clinical dilemma is to determine the malignant potential of an oral PML and, apart from clinical appearance and location, epithelial dysplasia has conventionally been the marker most used.<sup>8</sup> The limitations of this are discussed below.

### Occult primary oral cancers

It was recognized more than half a century ago that oral cancers may have a multicentric origin.<sup>9</sup> Molecular changes indicative of malignant potential do not necessarily produce clinically evident lesions and may be widespread, including outside the clinically identifiable lesion;<sup>10-12</sup> indeed, dysplastic or malignant changes may be detectable in clinically normal mucosa at sites far removed from an OSCC.<sup>13,14</sup> It is not surprising therefore, that second primary tumors are seen in up to about one-third of patients within a 5-year period.<sup>15</sup>

### Clinical diagnosis of OSCC

Since there may be widespread dysplastic mucosa (“field change”) or a second primary neoplasm, the whole oral mucosa should be examined often, along with examination of

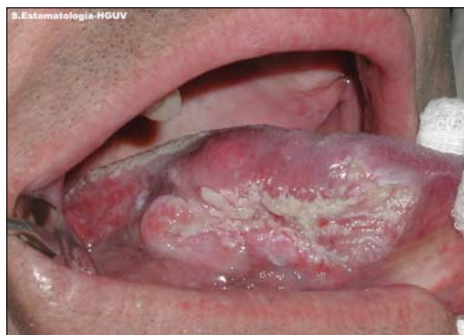

Fig. 1. Carcinoma of tongue.

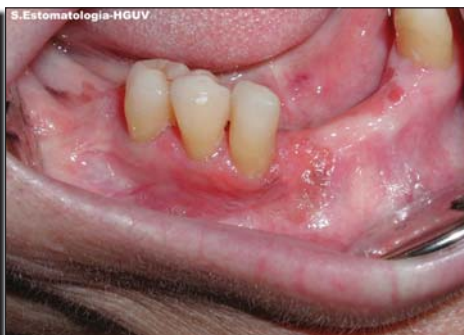

Fig. 2. Erythroplasia.

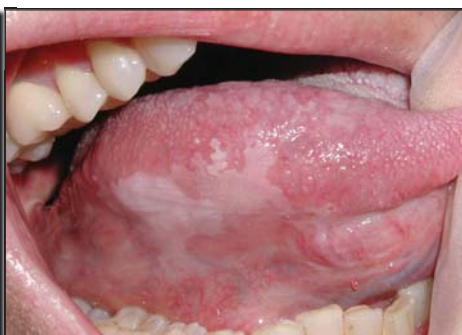

Fig. 3. Leukoplakia.

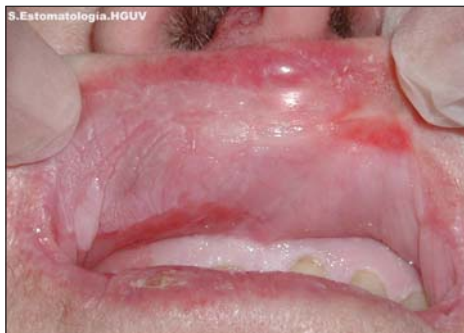

Fig. 4. Proliferative verrucous leukoplakia.

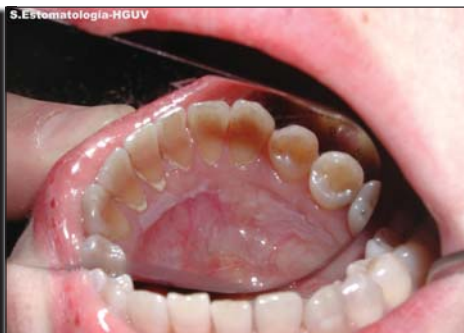

Fig. 5. Sublingual keratosis.

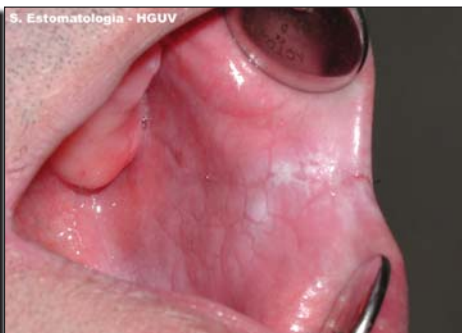

Fig. 6. Candidal leukoplakia.

Table 1. Potentially malignant oral lesions and conditions.

Approximate malignant potential	Lesion	Known etiological factors	Main clinical features
Very high (85%+)	Erythroplasia	Tobacco/alcohol	Red plaque
High in some instances (30%+)	Actinic cheilitis	Sunlight	White plaque/erosions
	Chronic candidosis (candidal leukoplakia)	Candida albicans	White or speckled white and red plaque
	Dyskeratosis congenita	Genetic	White plaques
	Leukoplakia (non-homogeneous)	Tobacco/alcohol	Speckled white and red plaque or nodular plaque
	Proliferative verrucous leukoplakia	Human papillomavirus (HPV): most often no history of tobacco/alcohol	White or speckled white and red or nodular plaque
	Sublingual keratosis	Tobacco/alcohol	White plaque
	Submucous fibrosis	Areca nut	Immobile pale mucosa
Low (<5%)	Syphilitic leukoplakia	Treponema pallidum	White plaque
	Atypia in immunocompromised patients	HPV	White or speckled white and red plaque
	Leukoplakia (homogeneous)	Friction/tobacco/alcohol	White plaque
	Discoid lupus erythematosus	Autoimmune	White plaque/erosions
	Lichen planus	Idiopathic	White plaque/erosions
	Fanconi syndrome	Genetic; anemia	White plaques
	Paterson-Kelly-Brown syndrome (sideropenic dysphagia; Plummer-Vinson syndrome)	Iron deficiency	Post-cricoid web

the rest of the upper aerodigestive tract, and the cervical lymph nodes must always be carefully examined by palpation. Particular attention should be given to high incidence sites for OSCC, such as the lip (Fig. 7), floor of mouth, lingual vestibule and side of tongue.

Many OSCCs can be detected visually by a trained

examiner<sup>16</sup> but early OSCC can be asymptomatic, and may appear innocuous, and can be overlooked<sup>17</sup> especially if the examination is not thorough. A number of studies have suggested not only that dentists can screen patients, but so can trained auxiliaries, although the evidence for effectiveness of screening remains controversial.<sup>18-20</sup> Nevertheless, some experts

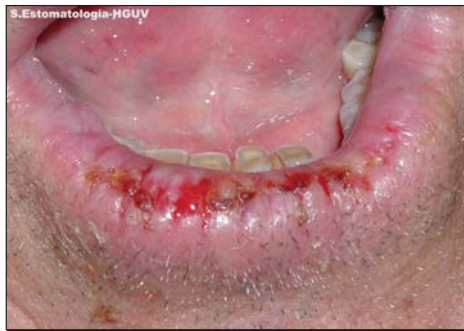

Fig. 7. Actinic cheilitis.

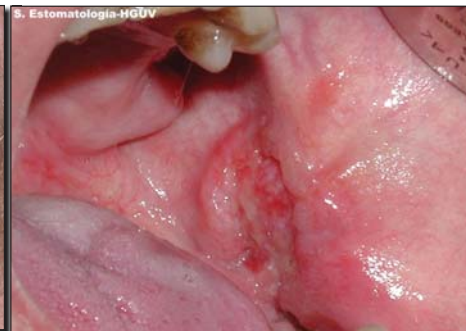

Fig. 8. Carcinoma.

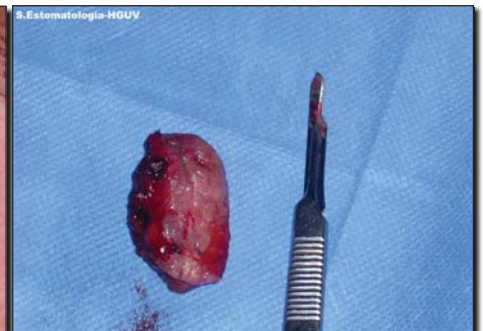


Fig. 9. Biopsy specimen.

Table 2. Warning features of oral carcinoma.

Red lesion (erythroplasia)  
 Mixed red/white lesion; irregular white lesion  
 Lump  
 Ulcer with fissuring or raised exophytic margins  
 Pain or numbness  
 Abnormal blood vessels supplying a lump  
 Loose tooth  
 Extraction socket not healing  
 Induration beneath a lesion, *i.e.*, a firm infiltration beneath the mucosa  
 Fixation of lesion to deeper tissues or to overlying skin or mucosa  
 Lymph node enlargement  
 Dysphagia  
 Weight loss

suggest that even highly trained health care professionals with broad experience cannot adequately identify all PMLs and early stage OSCC by visual inspection alone.<sup>21</sup>

Classic features of oral malignancy include ulceration, nodularity, induration and fixation<sup>8,22</sup> and cancer must be suspected especially when there is a single oral lesion persisting for more than 3 weeks. OSCC may present variously as (Table 2):

- an indurated lump/ulcer *i.e.* a firm infiltration beneath the mucosa (Fig. 8)
- a granular ulcer with fissuring or raised exophytic margins
- a white or mixed white and red lesion
- a red lesion (erythroplasia)
- a lump sometimes with abnormal supplying blood vessels
- a non-healing extraction socket
- a lesion fixed to deeper tissues or to overlying skin or mucosa
- other features (as shown in Table 2)
- cervical lymph node enlargement, especially if there is hardness in a lymph node or fixation. Enlarged nodes in a patient with oral carcinoma may be caused by infection, reactive hyperplasia secondary to the tumor, or metastatic disease. Occasionally (about 5%) a cervical lymph node enlargement is detected in the absence of any obvious primary tumor, where the most likely site for the primary in order of predilection is the tongue base, tonsil or nasopharynx.

However, the recognized classic features of OSCC (Table 1), such as ulceration, induration, elevation, bleeding, and cervical lymphadenopathy are features of advanced disease, not early stage disease,<sup>23</sup> and there is often a substantial delay in biopsy even when oral lesions display characteristics of frank cancers.<sup>24,25</sup> Biopsy needs to supplement clinical diagno-

Table 3. Currently available diagnostic technologies.

Biopsy and histopathological examination  
 Vital staining  
 Biomarkers  
 DNA ploidy (chromosomal polysomy)  
 Brush biopsy  
 Optical techniques

sis in order to establish or exclude, malignant disease and yet in reality, few leukoplakias (the most common PML), are ever biopsied.<sup>26</sup> In addition, OSCC, even if clinically visible, can resemble oral PML and some common benign oral lesions.

Thus, the reliable differentiation of malignant lesions from benign lesions by clinical inspection alone is unreliable.<sup>22,27</sup> Also, malignant transformation of potentially malignant lesions cannot be accurately predicted based solely upon clinical characteristics.

The only method currently available to reliably determine the diagnosis and give an indication of prognosis is the laboratory histopathological examination of a tissue sample since it is accepted that dysplasia may precede malignant change.<sup>28</sup> Therefore it is mandatory to biopsy any persistent mucosal lesion where there is not absolute confidence that the diagnosis is of a benign lesion. There should be a high index of suspicion, especially of a solitary lesion present for over 3 weeks. In practice therefore, all ulcerated, red, white or mixed solitary oral lesions persisting 3 weeks or more require biopsy evaluation.

**Current diagnostic techniques: Potential and limitations**

Early diagnosis and treatment are the goals.<sup>29,30</sup> Since the COE has undetermined sensitivity and specificity,<sup>31</sup> there is a need for more accurate diagnostic tools that can detect early lesions and determine either the potentially malignant or the benign nature of lesions. The need is great considering the large number of oral lesions encountered by dentists performing oral cancer screening, which amounts to 5-15% of screened patients.<sup>32-34</sup>

Currently available and developing tools are shown in Table 3. The available technologies are discussed here, with a synopsis of more embryonic emerging technologies later.

**Biopsy and histopathological examination**

The biopsy should be sufficiently large to include suspect and apparently normal tissue to give the pathologist a chance to make a diagnosis and not to have to request a further specimen. Since red rather than white areas are most likely to show any dysplasia present in the lesion, a biopsy should include the former.

Most biopsy wounds heal rapidly within days and it is important to ensure sufficient sampling to allow diagnosis and to take at least one ample specimen (Fig. 9). Some clinicians always take several biopsies at the first visit in order to avoid the delay and aggravation resulting from a negative pathology report in a patient who is strongly suspected as suffering from a malignant neoplasm. An excisional biopsy should be avoided since this will not remove a sufficient margin of tissue if the lesion is malignant and may limit the surgeon or radiotherapist, clinical evidence of the site, and character of the lesion.

Carcinoma is diagnosed when histopathological examination shows there is:

- dysplasia extending through the full thickness of the epithelium (severe dysplasia) and with,
- extension of the rete pegs into the underlying lamina propria, *i.e.* invasion across the basement membrane.

Progression of a PML to OSCC is as high as 36% when moderate or severe epithelial dysplasia is present and occurs in up to 50% in lesions with severe dysplasia. However, the histological findings of dysplasia indicate no more than that a lesion has a statistically increased risk of malignant change, and cannot be used for confident prediction of malignant change in any individual case. The prognostic value of histopathological features related to a primary OSCC tumor and the cervical lymph nodes has been reviewed.<sup>35</sup> Emphasis is given to practical aspects of the histopathological assessment, potential inaccuracies, the importance of the partnership between surgeon and pathologist, the need for standardization throughout the histopathological assessment, and the value of accurate documentation of findings.

Furthermore, even histological examination of a specimen is fraught with potential pitfalls and is subjective. A major problem in PML is to ensure that the biopsy is taken of the area most likely to contain the greatest number of cellular changes suggestive of premalignancy (dysplasia): to this end, red rather than white areas should be selected for biopsy. Vital staining may facilitate this (see below).

False negative results are still occasionally possible from incisional biopsy and, even where dysplasia has been excluded in a leukoplakia by incisional biopsy, studies have shown that the lesions, if wholly excised, may prove to contain OSCC in up to 10%.<sup>36</sup> This is not surprising, given that molecular changes consistent with early malignant changes can be scattered through and beyond a potentially malignant clinical lesion.<sup>37,38</sup> Furthermore, pathologists have been shown to vary in their opinions, and even the same pathologist may offer a different opinion on different occasions if faced with exactly the same specimen.<sup>39-42</sup>

In light of the above, if the pathology report denies malignancy, and yet clinically this is suspected, then discussion with the pathologist and a re-biopsy are invariably indicated. However, not only is conventional histopathology not unequivocally reliable but the goal should surely be to detect not only malignant and potentially malignant clinical lesions, but ideally to reveal epithelial molecular or DNA changes indicative of early carcinogenesis even where clinical lesions are not seen. Therefore there has been a desire to develop new diagnostic methods that yield greater information about PML,

and tumors including their prognosis<sup>43</sup> and this is where biomarkers (molecular markers) could play an important role in eliciting changes undetectable by examination of conventional hematoxylin and eosin stained sections.

### Vital staining

Various attempts to clinically highlight probable dysplastic areas before biopsy have, unfortunately, not proven to be absolutely reliable but may be of some help where there is widespread "field change" such as seen in patients at high risk for OSCC. Toluidine blue (TB) staining is a simple and inexpensive diagnostic tool that uses a blue dye to highlight abnormal areas of mucosa. TB is a basic metachromatic nuclear stain which stains nuclear material of malignant lesions and PML but not normal mucosa, used by (a) the patient rinsing the mouth with 1% acetic acid for 20 seconds followed by a similar rinse with water twice for 20 seconds; (b) rinsing the mouth with 5-10 cc. 1% toluidine blue solution; and (c) rinsing with 1% acetic acid solution (5 oz.) for about 1 minute followed by a water rinse.

In the highest risk population, prior upper autodigestive tract cancer patients, TB has a higher sensitivity to detect carcinoma *in situ* (CIS) and OSCC when compared to a COE (96.7% and 40%, respectively).<sup>44</sup> False positive staining (when lesions stain blue, but no carcinoma is identified after a biopsy is taken) occurred in 8-10% of cases associated with keratotic lesions and the regenerating edges of ulcers and erosions.<sup>44</sup> Here, the probability of a false negative finding for invasive OSCC is low and the absolute number of false positive tests is expected to be reduced. The clinical appearance of a dark royal blue stain may be significantly related to the nuclear uptake of TB, compared to pale royal blue staining which may be unrelated to any histological feature.<sup>45</sup> Studies assessing TB have shown a sensitivity and specificity ranging from 93.5 to 97.8% and 73.3 to 92.9%, respectively.<sup>44,46,47</sup>

TB staining may identify high-risk oral PMLs with poor outcome<sup>48-50</sup> and positive TB staining may be related to genetic changes [allelic loss or loss of heterozygosity (LOH)] associated with progression to OSCC even in histologically benign lesions and lesions with mild dysplasia.<sup>48,49</sup> TB may also help pre-operatively; in one reported case of OSCC, there were malignant or pre-malignant cells more than 1 cm away, requiring a resection of a size that would not have been addressed during COE alone,<sup>51</sup> though, from the discussion above, it can be seen that even mucosa of a normal appearance might be expected to contain molecular changes of early carcinogenesis.

### Biomarkers

Since the introduction of molecular techniques such as examination for abnormal protein expression, including tumor suppressor genes (TSGs) and other genetic changes, molecular markers have revealed neoplastic changes in PML (and furthermore may predict involvement of tumor resection margins and lymph nodes, and prognosis).

The most predictive of the molecular markers thus far available and assessed in OSCC development include the TSG p53 protein expression, chromosomal polysomy (DNA ploidy), and changes (termed loss of heterozygosity; LOH) in chromosomes 3p or 9p (probably due to changes in the TSG p16).<sup>52</sup>

Table 4. Studies on brush biopsies.\*

Year	First author	Number of cases		Comments
1999	Sciubba <sup>59</sup>	647	Multicenter	Not all identified lesions subject to biopsy; inadequate specimens not included in analysis
2002	Christian <sup>60</sup>	930	Dentists and hygienists	89 had oral lesions. Seven abnormal brush biopsies; of four of these who had scalpel biopsy, one had dysplasia
2002	Svirsky <sup>61</sup>	298	Brush biopsies	Of 243 patients with abnormal brush biopsies, 93 had dysplasia (79) or carcinoma (14). 150 were negative for either dysplasia or carcinoma. 82% (243/298) of scalpel biopsy-positives had abnormal brush biopsies
2003	Potter <sup>62</sup>	115	Oral carcinomas	Four had had negative brush biopsies
2004	Poate <sup>63</sup>	112	OM referrals with clinically suspicious oral lesions	Six of 15 brush biopsies negative, had dysplasia or carcinoma on scalpel biopsy
2004	Scheifele <sup>64</sup>	80	Carcinoma or PML	All had brush and scalpel biopsies positive

\*See text for results of studies where brush biopsies have been supplemented by molecular markers.

The use of such biomarkers as adjuncts to routine histopathological examination may help prognostication and effective management of PMLs but their routine use is still hampered by the cost and complexity of the tests, the lack of facilities in some laboratories, and limited outcome studies to date.

More readily available markers, such as those of cell proliferation (Ki-67 antigen) and apoptosis (Bax, Bcl-2), may also play a diagnostic role: apoptotic Bcl-2 expression decreases significantly in dysplastic and early invasive lesions and then increases almost to normal tissue level in consequent stages while Ki-67 expression increases sharply in initial stages of OSCC, but significantly decreases in later stages.<sup>53</sup>

A more aggressive tumor behavior and worse prognosis may also be signified by changes in a range of biomarkers, such as reduced E-cadherin expression,<sup>54,55</sup> laminin (LN) $\gamma$ <sup>2</sup> chain expression,<sup>56</sup> and decreased tumor cell transmembrane proteoglycan syndecan-1.<sup>57</sup>

### DNA ploidy

DNA ploidy is the measurement of nuclear DNA content. This may provide a surrogate measure of gross genetic damage and this could act as a surrogate for individual molecular markers.

Normally, a non-dividing somatic cell contains a diploid amount of DNA in 23 pairs or 46 chromosomes. Just before cell division, the DNA is doubled and in mitosis; the 23 pairs of chromosomes are evenly distributed to two daughter cells. In somatic cells, if a doubling of the DNA during S-phase occurs without a subsequent cell division, the nucleus will then contain quadruples of the DNA, making the cell tetraploid. Multiple copies of DNA in excess of diploidy is termed polyploidy. If the chromosomes are not uniformly distributed to the daughter cells or if parts of chromosomes become detached, the chromosomal segregation during mitosis is termed unbalanced, a situation termed aneuploidy and commonly observed in many cancers.<sup>52,58</sup>

DNA ploidy can be measured fairly simply with automated image cytometry of nuclei obtained from routinely processed tissue samples and the expertise is available in many pathology laboratories. However, unfortunately there has been controversy over the ploidy results published from one Norwegian laboratory, which must now be repeated by other workers.

### Brush biopsy

The brush biopsy uses a small nylon brush to gather cytology samples then sent for computer scanning and analysis (Oral CDx) to identify and display individual cells. If suspect cells are identified, a pathologist then examines them to determine the final diagnosis and, in samples judged to be cancerous, a printout of the abnormal cells from the computer display and a written pathologist's report are returned to the clinician with the recommendation that a positive result be followed with a conventional incisional biopsy. The technique has proved rather controversial, with concern largely related to the question of false negative results (Table 4).

In the first published study,<sup>59</sup> of 945 patients in USA, the brush biopsy reportedly detected correctly all cases of OSCC, even when dentists did not suspect the presence of cancer from the lesion, but this trial represented a multi-center convenience sample, not all lesions were biopsied and inadequate specimens were excluded from the analysis. In a further US study,<sup>61</sup> brush biopsy results when compared with scalpel biopsy and histology to determine the positive predictive value of an abnormal brush biopsy finding showed that, of 243 patients with abnormal brush biopsies, 93 proved positive either for dysplasia (79) or carcinoma (14), and 150 were negative for either dysplasia or carcinoma, giving the positive predictive value of an abnormal brush biopsy of 38% (93/243). A UK audit<sup>62</sup> which retrospectively determined the sensitivity, specificity and positive and negative predictive values of brush biopsy in the diagnosis of PML in 112 patients showed the sensitivity of detection of dysplasia or OSCC to be 71.4% but the specificity was only 32%. The positive predictive value of an abnormal brush biopsy result was 44.1%, while the negative predictive value was 60%. Review of 115 diagnosed OSCC from another oral pathology service identified four patients who had previously undergone brush biopsy reported to be "negative for epithelial abnormality" (3.5%),<sup>63</sup> further suggesting that false negative reports are possible with the oral brush biopsy. Other workers have confirmed this and also raised concerns about frequent false positive results.<sup>65</sup>

Improved outcomes of brush biopsy may be obtained however, with the addition of molecular techniques. Brush biopsy specimens of 43 oral leukoplakias, 26 OSCCs, and the oral mucosa of four clinically normal volunteers were analyzed

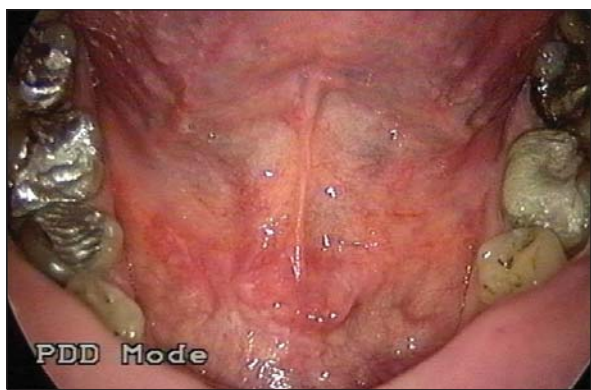

Fig. 10. Clinical view of floor of mouth before spectroscopy.

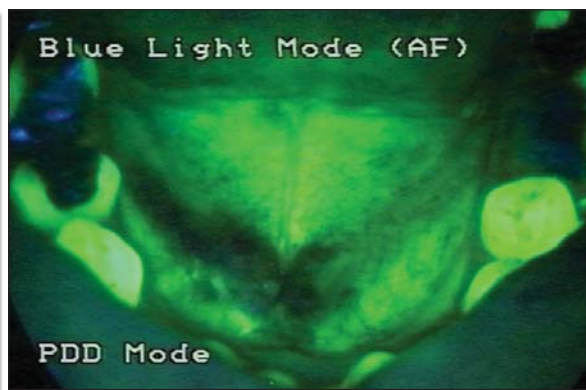


Fig. 11. Clinical view of floor of mouth after spectroscopy.

Table 5. Studies on Vizilite.

Year	First author	Number of cases		Comments
2004	Huber <sup>73</sup>	150	Consecutive	One lesion detected by fluorescence not by COE; lesions visible on COE were slightly easier visualized by fluorescence
2005	Ram <sup>74</sup>	40	Prior oral cancer or PML	Small sample; little benefit from fluorescence
2006	Epstein <sup>75</sup>	134	Prior oral lesions	Two lesions detected by fluorescence not by COE; but visible on COE were not seen on fluorescence
2006	Farah <sup>76</sup>	55	Oral Medicine referrals with white lesions	One lesion detected by fluorescence not by COE
2006	Kerr <sup>77</sup>	501	>40 years old and tobacco users	Six lesions detected by fluorescence not by COE; but were visible on repeat COE
2007	Oh <sup>78</sup>	100	Dental screen	No significant benefit over COE

for TSG p53 mutations, which were found in 57.7% of OSCC, 39.5% of leukoplakias and in 0% controls.<sup>66</sup> A prospective study<sup>67</sup> assessing the diagnostic accuracy of brush biopsies in combination with DNA image cytometry showed a sensitivity of 97.8%, specificity of 100%, positive predictive value 100%, and negative predictive value 98.1%. The same group showed cytology with DNA-cytometry to be a highly sensitive, specific and non-invasive method resulting in a sensitivity of 100% and a specificity of 97.4%.<sup>68</sup> Silver stained nucleolar organizer regions (AgNOR) analysis may be another useful adjunct.<sup>69</sup> In a further study<sup>69</sup> by the same group<sup>69</sup> using AgNOR, sensitivity of the cytological diagnosis alone for the detection of OSCCs was 92.5%, specificity 100%, positive predictive value was 100% and negative predictive value was 84.6%. Applying these methods to 12 doubtful or suspicious cytological diagnoses, these workers were able to correctly establish the diagnosis of malignancy in 10 cases of histologically-proven OSCC and to reveal benignity in two histologically-proven cases, thus achieving positive and negative predictive values of 100% each.

The jury is thus still out on the value of the brush biopsy but nevertheless, it should be borne in mind that the results from scalpel biopsies are also not infallible (as discussed above). Indeed, brush biopsy may detect some OSCCs missed on scalpel biopsy. For example, one report of four patients presenting with early OSCC showed the tumors to be detected cytologically on brush biopsies including DNA-image cytometry as an adjunctive method, in macroscopically suspicious lesions despite initial scalpel biopsies showing no evidence of cancer nor of severe dysplasia. The occurrence of early OSCC was finally confirmed histologically on a repeat scalpel biopsy.<sup>70</sup> Further well-designed studies in non-expert settings

and well-designed prospective studies are needed.

### Optical systems

Interaction of light with tissues may highlight changes in tissue structure and metabolism. Optical spectroscopy systems to detect changes rely on the fact that the optical spectrum derived from a tissue will contain information about the histological and biochemical characteristics of that tissue. Such optical adjuncts may assist in identification of mucosal lesions including PML and OSCC, assist in biopsy site selection and enhance visibility of surface texture and margins of lesions and may also assist in identification of cellular and molecular abnormalities not visible to the naked eye on routine examination (Figs. 10, 11).

There are a number of optical systems that can yield similar types of information approaching the detail of histopathology and theoretically at least, in a more quantifiable and objective fashion, in real-time, non-invasively and *in situ*.<sup>71,72</sup>

Early detection of mucosal lesions can be enhanced by the use of a dilute acetic acid rinse and observation under a chemiluminescent light (ViziLite<sup>®</sup>). Several studies are summarized in Table 5. In one study<sup>78</sup> of 100 patients who presented for dental screening and were examined by COE (under incandescent light) before and after a 1-minute rinse with 1% acetic acid, and then once again using the ViziLite, 57 had clinically diagnosable benign lesions (*e.g.* linea alba, leukoedema) and 29 clinically undiagnosable lesions initially, but after the acetic acid rinse, six additional diagnosable lesions (linea alba) and three undiagnosable lesions were found. In a multicenter study,<sup>75</sup> increased visibility of lesions visible by COE was reported. In that and other studies,<sup>79</sup> ViziLite revealed occasional lesions not

Table 6. Studies on VelScope.

Year	First author	Number of cases		Comments
2006	Lane <sup>92</sup>	44	Prior oral cancer or PML	All lesions detected by fluorescence were seen by COE
2006	Poh <sup>93</sup>	3	Non-consecutive cases	All lesions detected by fluorescence were not seen by COE

seen under COE but, occasionally, the converse has been the case, so the jury again is out on the real benefits.

Early detection of mucosal lesions can be enhanced by the use of fluorescence. All tissues have a tendency to glow (fluoresce) in the dark, either spontaneously (auto-fluorescence) or if an external sensitizer is applied to the tissues. The tissue fluoresces due to the presence of fluorescent chromophores (fluorophores) within the cells. Commonly detected fluorophores include nicotine adenine dinucleotide hydrogenase, collagen, elastin, flavin adenine dinucleotides, hemoglobin and vascular supply; and oral microbial flora, and they vary in different tissues including different sites in the mouth. Tissue changes can affect the fluorophores and tissue fluorescence, and this may facilitate detection of lesions not detectable with the naked eye under normal incandescent white light.<sup>80-91</sup>

Fluorescence and changes suggestive of PML or OSCC can already be detected using commercially available photographic techniques (e.g. Storz,<sup>b</sup> Pentax,<sup>c</sup> Zillix<sup>d</sup>), but most of these also have relatively low sensitivity and specificity. Preliminary studies using direct visualization (VelScope<sup>e</sup>) however, have been very encouraging when assessed in patients with OSCC (Table 6).<sup>92-94</sup> These early studies must be extended into multicenter controlled trials in patients at and not at risk of OSCC, and with experts and non-expert providers.

Some other potential diagnostic systems are listed in Table 7.

### Saliva-based oral cancer diagnostics

Exfoliative cell samples have been used to detect genetic alterations in the oral epithelium of patients at high risk from oral cancer,<sup>95</sup> and to detect microsatellite alterations in OSCC.<sup>96</sup>

The concept of a saliva test to diagnose OSCC is even more appealing.<sup>96-104</sup> Promoter hypermethylation patterns of TSG p16, O6-methylguanine-DNA-methyltransferase, and death-associated protein kinase have been identified in the saliva of head and neck cancer patients.<sup>105</sup> Forensic science has since shown that saliva can contain a number of messenger ribonucleic acid (mRNA) fragments including salivary specific statherin, histatin 3, and the proline-rich proteins PRB1, PRB2 and PRB3, as well as the ubiquitously expressed spermidine N1 acetyl transferase (SAT),  $\beta$ -actin, and glyceraldehyde-3-phosphate dehydrogenase (GAPDH).<sup>106</sup> The mRNAs in saliva such as  $\beta$ -actin, SAT and interleukin-8 are relatively stable despite the presence of salivary ribonucleases.<sup>97,98,102,106</sup> mRNAs in saliva have been tested in over 300 saliva samples from OSCC patients and healthy people, and the signature was always present in higher levels in the saliva of OSCC patients than in saliva from healthy people, with an overall accuracy rate of about 85%.<sup>107</sup> Four salivary mRNAs (OLF/EBF associated zinc finger protein[OAZ], SAT, IL8, and IL1b) collectively have a discriminatory power of 91% sensitivity and specificity for OSCC detection.<sup>101</sup> This avenue of research is thus clearly most appealing.

Table 7. Other potential future diagnostic technologies.<sup>112-143</sup>

Laser-induced fluorescence spectroscopy
Light-induced fluorescence spectroscopy
Elastic scattering spectroscopy
Raman spectroscopy
Photoacoustic imaging
Photon fluorescence
Orthogonal polarization spectral (OPS) imaging
Quantum dots
Optical coherence tomography (OCT)
Trimodal spectroscopy
Doppler OCT
Nuclear magnetic resonance spectroscopy
Chromoendoscopy
Narrow band imaging (NBI),
Immunophotodiagnostic techniques
Differential path length spectroscopy
2 photon fluorescence
2 <sup>nd</sup> harmonic generation
Terahertz imaging

CD44, a multistructural and multifunctional cell surface transmembrane glycoprotein molecule involved in cell proliferation, cell differentiation, cell migration, angiogenesis, presentation of cytokines, chemokines, and growth factors to the corresponding receptors, and docking of proteases at the cell membrane, as well as in signaling for cell survival, is also detectable in saliva. CD44 isoforms containing the variant 3 (v3) exon include a growth factor binding site and may be involved in OSCC progression.<sup>108,109</sup> Salivary soluble CD44 (solCD44) levels were found significantly raised in head and neck cancer (HNSCC) patients compared with normal controls and detected 79% of mucosally invasive HNSCC using preliminary cutoff points. However, SolCD44 levels did not vary significantly with tumor size, stage, recurrence, history of radiation treatment, or tobacco and alcohol risk factors.<sup>110</sup> Further work is awaited as to the utility of CD44 as a cancer marker.

Finally, high salivary counts of *Capnocytophaga gingivalis*, *Prevotella melaninogenica* and *Streptococcus mitis* have been found in patients with OSCC,<sup>111</sup> but the suggestion that this could be a reliable diagnostic indicator is difficult to support.

Multicenter studies in large populations at risk of cancer and those at low risk are needed in order to verify the reliability of these saliva-based tests.

Laser-induced fluorescence spectroscopy used to examine OSCC in the hamster buccal pouch model shows increased fluorescence in malignant areas.<sup>112</sup>

Light-induced fluorescence spectroscopy can distinguish between benign (normal and hyperkeratosis) and dysplasia with a sensitivity of 92% and a specificity of 95%.<sup>113</sup> Fluorescence photography detected OSCC with a sensitivity of 91% and specificity of 85%. The relatively low sensitivity and specificity of auto-fluorescence can be markedly improved by adding an exogenous chemical such as aminolevulinic acid (ALA), ap-

plied systemically or topically. Typically in the oral cavity, a mouthwash is applied and the ALA is taken up into the cells and metabolized to protoporphyrin 9 which fluoresces. Interrogation with blue light results in a fluorescence signal which is then captured using a CCD camera which is mosaicated and allows specific measurement of red and green fluorescence.<sup>114-119</sup> A fluorescent image system associated with color image fusion algorithm has also been reported with positive results.<sup>120</sup> Laser induced fluorescence (LIF) spectroscopy has been developed for the diagnosis of cancer using an algorithm based on nonlinear maximum representation and discrimination feature (MRDF) method.<sup>121-123</sup>

Elastic scattering spectroscopy requires light to be fired into tissue in a short burst and the resulting signal is detected by fibers and fed into a spectrometer interfaced with a computer. When light enters the tissue it may be elastically scattered, inelastically scattered, or absorbed. The amount the light scatters depends on nuclear size, shape and orientation *i.e.* the items that a pathologist examines. In addition, light will be scattered by intracellular organelles and there will also be other changes depending on tissue thickness. Elastic scattering spectroscopy recordings from normal and OSCC tissue may differ<sup>124-126</sup> and studies on patients with leukoplakia have shown a sensitivity of 72% and specificity of 75% in differentiating cancer and dysplasia from benign lesions.<sup>127</sup>

Raman spectroscopy looks at the vibrational changes in tissue that parallel changes in chemical composition, and is sensitive (for example) to changes in DNA content. Raman spectroscopy is widely used in chemical analysis and is based on “inelastic” light scattering since the detected wavelengths are different from that of the applied light. Fourier transform infrared (FTIR)/Raman spectroscopy has been successfully applied for the diagnosis of OSCC in the hamster cheek pouch model with 100% sensitivity and 55% specificity.<sup>128</sup>

Photoacoustic imaging relies on the measurement of light-induced acoustic emission. When a laser pulse passes through a tissue, some of the energy is absorbed and generates a sound wave. The image contrast is provided by native light absorbing chromophores such as hemoglobin or other agents such as nanoparticles and dyes. This can be used to look at blood oxygenation and hemoglobin concentration, but it can also be used to image microvascular networks that may be important in early malignancy.<sup>129-132</sup>

Photon fluorescence uses second harmonic generation (SHG) to detect light emerging from materials at half the wavelength (and twice the energy) of the light entering the material. This multiphoton process only occurs in materials with a particular crystalline structure and optical properties and, in biological systems, only collagen fibrils fulfill these criteria. SHG can be used to detect collagen IV and the lack of it around an invasive carcinoma; detailed structural information at micron scale resolution and indications of pathology can thereby be obtained.<sup>133</sup>

Orthogonal polarization spectral (OPS) imaging for *in vivo* visualization of the human microcirculation facilitates high resolution images of the oral mucosa. OSCC are characterized by chaotic and dilated vessels accompanied by numerous areas of hemorrhage and this may be detectable by OPS.<sup>134</sup>

Quantum dots are particles of one nanometer in diameter whose action is based on the fluorescence phenomenon. They absorb photons of white light within their core and re-emit nanochromatic light at a specific wavelength, and the re-emitted light is so bright that it is possible to detect it even if only one cell-crystal complex is excited. Quantum dots absorb light over a wide spectrum so it is possible to excite many dots with a single light source, each emitting a different color, thereby allowing detection of multiple markers at the same time.

Optical coherence tomography (OCT), well established in the ophthalmological literature where OCT is used to examine the retina, has the potential to be applied in OSCC diagnosis. OCT combines interferometry with low-coherence light to produce high-resolution tissue imaging<sup>135</sup> and it can detect carcinogenesis in epithelial and sub-epithelial tissues in hamster cheek pouches with an overall sensitivity and specificity of 80%.<sup>136</sup> Newer systems such as Fourier transformed OCT, a complex interferometric optical tomographic system which offers sub-micrometer resolution, has the potential to give great resolution in a non-invasive way and should yield information about the early changes associated with invasive cancer.

Trimodal spectroscopy uses three independent optical diagnostic techniques (fluorescent spectroscopy, diffuse scattering spectroscopy and elastic scattering spectroscopy) to achieve better results, reaching sensitivity and specificity of 96% in differentiating between normal oral mucosa and dysplasia and OSCC and a sensitivity of 64% and specificity of 90% in distinguishing between dysplasia and OSCC.<sup>84</sup> Trimodal spectroscopy, although having the advantage of being accurate is however, expensive and time-consuming.

Other potential systems include Doppler OCT, nuclear magnetic resonance spectroscopy, chromoendoscopy, narrow band imaging (NBI), immunophotodiagnostic techniques, differential path length spectroscopy, 2 photon fluorescence, 2<sup>nd</sup> harmonic generation, and terahertz imaging.<sup>137-143</sup>

## Summary

All imaging techniques require multicenter controlled trials in high risk patients and low risk populations with histologic outcomes and cross-sectional/longitudinal trials, but adjuncts for detection and diagnosis have the potential to assist in early detection, leading to early diagnosis and improved treatment outcomes.

- a. Zila Pharmaceuticals, Phoenix, AZ, USA.
- b. Karl Storz GmbH & Co. KG, Tuttlingen, Germany.
- c. Pentax, Tokyo, Japan.
- d. LED Dental, Inc., White Rock, BC, Canada.

Dr. Scully is Professor, and Mr. Hopper is Senior Lecturer, UCL Eastman Dental Institute, University College London, London, United Kingdom. Dr. Bagan is Professor, University of Valencia, General University Hospital, Valencia, Spain. Dr. Epstein is Head, Department of Oral Medicine, University of Illinois at Chicago, Chicago, Illinois, USA.

## References

1. Waldron CA, Shafer WG. Leukoplakia revisited. A clinicopathologic study 3256 oral leukoplakias. *Cancer* 1975;36:1386-1392.
2. Wright JM. Oral precancerous lesions and conditions. *Semin Dermatol* 1994;13:125-131.
3. Sankaranarayanan R. Screening for cervical and oral cancers in India is feasible and effective. *Natl Med J India* 2005;18: 281-284.



4. Sankaranarayanan R, Ramadas K, Thomas G, Muwonge R, Thara S, Mathew B, Rajan B. Trivandrum oral cancer screening study group. Effect of screening on oral cancer mortality in Kerala, India: A cluster-randomised controlled trial. *Lancet* 2005 Jun 4-10;365(9475):1927-1933.
5. Massano J, Regateiro FS, Januario G, Ferreira A. Oral squamous cell carcinoma: Review of prognostic and predictive factors. *Oral Surg Oral Med Oral Pathol* 2006;102:67-76.
6. Sciubba JJ. Oral leukoplakia. *Crit Rev Oral Biol Med* 1995;6:147-160.
7. Scully C, Cawson R. Potentially malignant oral lesions. *J Epidemiol Biostat* 1996;1:3-12.
8. Mashberg A, Samit A. Early diagnosis of asymptomatic oral and oropharyngeal squamous cancers. *CA Cancer J Clin* 1995;45:328-351.
9. Slaughter DP, Southwick HW, Smejkal W. Field cancerization in oral stratified squamous epithelium; clinical implications of multicentric origin. *Cancer* 1953;6:963-968.
10. Braakhuis BJ, Tabor MP, Kummer JA, Leemans CR, Brakenhoff RH. A genetic explanation of Slaughter's concept of field cancerization: Evidence and clinical implications. *Cancer Res* 2003;63:1727-1730.
11. Braakhuis BJ, Leemans CR, Brakenhoff RH. Expanding fields of genetically altered cells in head and neck squamous carcinogenesis. *Semin Cancer Biol* 2005;15:113-120.
12. Tabor MP, Brakenhoff RH, Ruijter-Schippers HJ, Kummer JA, Leemans CR, Braakhuis BJ. Genetically altered fields as origin of locally recurrent head and neck cancer: A retrospective study. *Clin Cancer Res* 2004;10:3607-3613.
13. Thomson PJ. Field change and oral cancer: New evidence for widespread carcinogenesis? *Int J Oral Maxillofac Surg* 2002;31:262-266.
14. Thomson PJ, Hamadah O. Cancerisation within the oral cavity: The use of "field mapping biopsies" in clinical management. *Oral Oncol* 2007;43:20-26.
15. Lippman SM, Hong WK. Second malignant tumors in head and neck squamous cell carcinoma: The overshadowing threat for patients with early-stage disease. *Int J Radiat Oncol Biol Phys* 1989;17:691-694.
16. Sankaranarayanan R, Fernandez GL, Lence AJ, Pisani P, Rodriguez SA. Visual inspection in oral cancer screening in Cuba: A case-control study. *Oral Oncol* 2002;38:131-136.
17. Shugars DC, Patton LL. Detecting, diagnosing, and preventing oral cancer. *Nurse Pract* 1997;22:105,109-10,113-115.
18. Downer MC, Moles DR, Palmer S, Speight PM. A systematic review of measures of effectiveness in screening for oral cancer and precancer. *Oral Oncol* 2006;42:551-560.
19. Kujan O, Glenny AM, Sloan P. Screening for oral cancer. *Lancet* 2005 Oct 8;366(9493):1265-1266; author reply 1266.
20. Kujan O, Glenny AM, Oliver RJ, Thakker N, Sloan P. Screening programmes for the early detection and prevention of oral cancer. *Cochrane Database Syst Rev* 2006;3:CD004150.
21. Silverman S Jr. Early diagnosis of oral cancer. *Cancer* 1988;62:1796-1799.
22. Mashberg A, Merletti F, Boffetta P, Gandolfo S, Ozzello F, Fracchia F, Terracini B. Appearance, site of occurrence, and physical and clinical characteristics of oral carcinoma in Torino, Italy. *Cancer* 1989;63:2522-2527.
23. Mashberg A, Feldman LJ. Clinical criteria for identifying early oral and oropharyngeal carcinoma: Erythroplasia revisited. *Am J Surg* 1988;156:273-275.
24. Scully C, Malamos D, Levers BG, Porter SR, Prime SS. Sources and patterns of referrals of oral cancer: Role of general practitioners. *Br Med J (Clin Res Ed)* 1986;293:599-601.
25. Dimitroulis G, Reade P, Wiesenfeld D. Referral patterns of patients with oral squamous cell carcinoma, Australia. *Eur J Cancer B Oral Oncol* 1992;28B:23-27.
26. Bouquot JE, Gorlin RJ. Leukoplakia, lichen planus, and other oral keratoses in 23,616 white Americans over the age of 35 years. *Oral Surg Oral Med Oral Pathol* 1986;61:373-381.
27. Silverman S. Oral cancer. *Semin Dermatol* 1994;13:132-137.
28. Lumerman H, Freedman P, Kerpel S. Oral epithelial dysplasia and the development of invasive squamous cell carcinoma. *Oral Surg Oral Med Oral Pathol* 1995;79:321-329.
29. Woolgar J. A pathologist's view of oral cancer in the North West. *Br Dent J* 1995;54:14-16.
30. Sciubba JJ. Oral cancer. The importance of early diagnosis and treatment. *Am J Clin Dermatol* 2001;2:239-251.
31. US Preventive Services Task Force. *Guide to clinical preventive services*. 1996. Baltimore, Williams and Wilkins.
32. Burzynski NJ, Firriolo FJ, Butters JM, Sorrell CL. Evaluation of oral cancer screening. *J Cancer Educ* 1997;12:95-99.
33. Bouquot JE. Common oral lesions found during a mass screening examination. *J Am Dent Assoc* 1986;112:50-57.
34. Malaovalla AM, Silverman S, Mani NJ, Bilimoria KF, Smith LW. Oral cancer in 57,518 industrial workers of Gujarat, India: A prevalence and followup study. *Cancer* 1976;37:1882-1886.
35. Woolgar JA. Histopathological prognosticators in oral and oropharyngeal squamous cell carcinoma. *Oral Oncol* 2006;42:229-239.
36. Chiesa F, Sala L, Costa L, Moglia D, Mauri M, Podrecca S, Andreola S, Marchesini R, Bandieramonte G, Bartoli C. Excision of oral leukoplakias by CO<sub>2</sub> laser on an out-patient basis: A useful procedure for prevention and early detection of oral carcinomas. *Tumori* 1986;72:307-312.
37. Califano J, Westra WH, Meininger G, Corio R, Koch WM, Sidransky D. Genetic progression and clonal relationship of recurrent premalignant head and neck lesions. *Clin Cancer Res* 2000;6:347-352.
38. Braakhuis BJ, Leemans CR, Brakenhoff RH. A genetic progression model of oral cancer: Current evidence and clinical implications. *J Oral Pathol Med* 2004;33:317-322.
39. Abbey LM, Kaugars GE, Gunsolley JC, Burns JC, Page DG, Svirsky JA, Eisenberg E, Krutchkoff DJ, Cushing M. Intra-examiner and inter-examiner reliability in the diagnosis of oral epithelial dysplasia. *Oral Surg Oral Med Oral Pathol* 1995;80:188-191.
40. Karabulut A, Reibel J, Therkildsen MH, Praetorius F, Nielsen HW, Dabelsteen E. Observer variability in the histologic assessment of oral premalignant lesions. *J Oral Pathol Med* 1995;24:198-200.
41. Fischer DJ, Epstein JB, Morton TH, Schwartz SM. Interobserver reliability in the histopathologic diagnosis of oral premalignant and malignant lesions. *J Oral Pathol Med* 2004;33:65-70.
42. Fischer DJ, Epstein JB, Morton TH, Schwartz SM. Reliability of histologic diagnosis of clinically normal intraoral tissue adjacent to clinically suspicious lesions in former upper aerodigestive tract cancer patients. *Oral Oncol* 2005;41:489-496.
43. Mehrotra R, Gupta A, Singh M, Ibrahim R. Application of cytology and molecular biology in diagnosing premalignant or malignant oral lesions. *Mol Cancer* 2006 Mar 23;5:11.
44. Epstein JB, Feldman R, Dolor RJ, Porter SR. The utility of tonium chloride rinse in the diagnosis of recurrent or second primary cancers in patients with prior upper aerodigestive tract cancer. *Head Neck* 2003;25:911-921.
45. Gandolfo S, Pentenero M, Broccoletti R, Pagano M, Carozzo M, Scully C. Toluidine blue uptake in potentially malignant oral lesions *in vivo*: Clinical and histological assessment. *Oral Oncol* 2006;42:89-95.
46. Mashberg A. Reevaluation of Toluidine Blue application as a diagnostic adjunct in the detection of asymptomatic oral squamous carcinoma. *Cancer* 1980;46:754-763.
47. Rosenberg D, Cretin S. Use of meta analysis to evaluate tonium chloride in oral cancer screening. *Oral Surg Oral Med Oral Pathol* 1989;67:621-627.
48. Zhang L, Williams M, Poh CF, Laronde D, Epstein J, Durham S, Nakamura H, Borean K, Hovan A, Le ND, Hislop G, Priddy R, Hay J, Lam WL, Rosin MP. Toluidine blue staining identifies high-risk primary oral premalignant lesions with poor outcome. *Cancer Res* 2005;65:8017-8021.
49. Guo Z, Yamaguchi K, Sanchez-Cespedes M, Westra WH, Koch WM, Sidransky D. Allelic losses in OraTest-directed biopsies of patients with prior upper aerodigestive tract malignancy. *Clin Cancer Res* 2001;7:1963-1968.
50. Silverman S Jr, Migliorati C, Barbosa J. Toluidine blue staining in the detection of oral precancerous and malignant lesions. *Oral Surg Oral Med Oral Pathol* 1984;57:379-382.
51. Missmann M, Jank S, Laimer K, Gassner R. A reason for the use of toluidine blue staining in the presurgical management of patients with oral squamous cell carcinomas. *Oral Surg Oral Med Oral Pathol* 2006;102:741-743.
52. Scully C, Sudbo J, Speight PM. Progress in determining the malignant potential of oral lesions. *J Oral Pathol Med* 2003;32:251-256.
53. Derka S, Vairaktaris E, Papakosta V, Vassiliou S, Acil Y, Vylliotis A, Spyridonidou S, Lazaris AC, Mourouzis C, Kokkori A, Moulavasilis P, Perrea D, Donta I, Yapijakis C, Patsouris E. Cell proliferation and apoptosis culminate in early stages of oral oncogenesis. *Oral Oncol* 2006;42:540-550.
54. Diniz-Freitas M, Garcia-Caballero T, Antunez-Lopez J, Gandara-Rey JM, Garcia-Garcia A. Reduced E-cadherin expression is an indicator of unfavourable prognosis in oral squamous cell carcinoma. *Oral Oncol* 2006;42:190-200.
55. Hamidi S, Salo T, Kainulainen T, Epstein J, Lerner K, Larjava H. Expression of alpha(v)beta6 integrin in oral leukoplakia. *Br J Cancer* 2000;82:1433-1440.
56. Kuratomi Y, Kumamoto M, Kidera K, Toh S, Masuda M, Nakashima T, Inokuchi A. Diffuse expression of laminin gamma 2 chain in disseminating and infiltrating cancer cells indicates a highly malignant state in advanced tongue cancer. *Oral Oncol* 2006;42:73-76.

57. Mathe M, Suba Z, Nemeth Z, Tatrai P, Fule T, Borgulya G, Barabas J, Kovalszky I. Stromal syndecan-1 expression is an adverse prognostic factor in oral carcinomas. *Oral Oncol* 2006;42:493-500.
58. Pektas ZO, Keskin A, Gunhan O, Karslioglu Y. Evaluation of nuclear morphometry and DNA ploidy status for detection of malignant and premalignant oral lesions: Quantitative cytologic assessment and review of methods for cytomorphometric measurements. *J Oral Maxillofac Surg* 2006;64:628-635.
59. Scuibba JJ. Improving detection of precancerous and cancerous oral lesions. Computer-assisted analysis of the oral brush biopsy. U.S. Collaborative OralCDx Study Group. *J Am Dent Assoc* 1999;130:1445-1457.
60. Christian DC. Computer-assisted analysis of oral brush biopsies at an oral cancer screening program. *J Am Dent Assoc* 2002;133:357-362.
61. Svirsky JA, Burns JC, Carpenter WM, Cohen DM, Bhattacharyya I, Fantasia JE, Lederman DA, Lynch DP, Scuibba JJ, Zunt SL. Comparison of computer-assisted brush biopsy results with follow up scalpel biopsy and histology. *Gen Dent* 2002;50:500-503.
62. Poate TW, Buchanan JA, Hodgson TA, Speight PM, Barrett AW, Moles DR, Scully C, Porter SR. An audit of the efficacy of the oral brush biopsy technique in a specialist Oral Medicine unit. *Oral Oncol* 2004;40:829-834.
63. Potter TJ, Summerlin DJ, Campbell JH. Oral malignancies associated with negative transepithelial brush biopsy. *J Oral Maxillofac Surg* 2003;61:674-677.
64. Scheifele C, Schmidt-Westhausen AM, Dietrich T, Reichart PA. The sensitivity and specificity of the OralCDx technique: Evaluation of 103 cases. *Oral Oncol* 2004;40:824-828.
65. Rick GM. Oral brush biopsy: The problem of false positives. *Oral Surg, Oral Med, Oral Pathol* 2003;96:252.
66. Scheifele C, Schlechte H, Bethke G, Reichart PA. Detection of TP53-mutations in brush biopsies from oral leukoplakias. *Mund Kiefer Gesichtschir* 2002;6:410-414. (In German).
67. Remmerbach TW, Mathes SN, Weidenbach H, Hemprich A, Bocking A. Noninvasive brush biopsy as an innovative tool for early detection of oral carcinomas. *Mund Kiefer Gesichtschir* 2004;8:229-236. (In German).
68. Maraki D, Becker J, Boecking A. Cytologic and DNA-cytometric very early diagnosis of oral cancer. *J Oral Pathol Med* 2004;33:398-404.
69. Remmerbach TW, Weidenbach H, Muller C, Hemprich A, Pomjanski N, Buckstege B, Bocking A. Diagnostic value of nucleolar organizer regions (AgNORs) in brush biopsies of suspicious lesions of the oral cavity. *Anal Cell Pathol* 2003;25:139-146.
70. Remmerbach TW, Weidenbach H, Hemprich A, Bocking A. Earliest detection of oral cancer using non-invasive brush biopsy including DNA-image-cytometry: Report on four cases. *Anal Cell Pathol* 2003;25:157-158.
71. Swinson B, Jerjes W, El-Maaytah M, Norris P, Hopper C. Optical techniques in diagnosis of head and neck malignancy. *Oral Oncol* 2006; 42: 221-228.
72. Suhr MA, Hopper C, Jones L, George JG, Bown SG, MacRobert AJ. Optical biopsy systems for the diagnosis and monitoring of superficial cancer and precancer. *Int J Oral Maxillofac Surg* 2000;29:453-457.
73. Huber MA, Bsoul SA, Terezhalmay GT. Acetic acid wash and chemiluminescent illumination as an adjunct to conventional oral soft tissue examination for the detection of dysplasia: A pilot study. *Quintessence Int* 2004;35:378-384.
74. Ram S, Siar CH. Chemiluminescence as a diagnostic aid in the detection of oral cancer and potentially malignant epithelial lesions. *Int J Oral Maxillofac Surg* 2005;34:521-527.
75. Epstein JB, Gorsky M, Lonky S, Silverman S Jr, Epstein JD, Bride M. The efficacy of oral lumenoscopy (ViziLite) in visualizing oral mucosal lesions. *Spec Care Dentist* 2006;26:171-174.
76. Farah CS, McCullough MJ. A pilot case control study on the efficacy of acetic acid wash and chemiluminescent illumination (ViziLitetrade mark) in the visualisation of oral mucosal white lesions. *Oral Oncol* 2007; 43:820-824.
77. Kerr AR, Sirois DA, Epstein JB. Clinical evaluation of chemiluminescent lighting: An adjunct for oral mucosal examinations. *J Clin Dent* 2006;17:59-63.
78. Oh ES, Laskin DM. Efficacy of the ViziLite system in the identification of oral lesions. *J Oral Maxillofac Surg* 2007;65:424-426.
79. Rosin MP, Poh CF, Guillard M, Williams PM, Zhang L, Macaulay C. Visualization and other emerging technologies as change makers for oral cancer prevention. *Ann N Y Acad Sci* 2007;1098:167-183.
80. Gillenwater A, Jacob R, Ganeshappa R, Kemp B, El-Naggar AK, Palmer JL, Clayman G, Mitchell MF, Richards-Kortum R. Noninvasive diagnosis of oral neoplasia based on fluorescence spectroscopy and native tissue autofluorescence. *Arch Otolaryngol Head Neck Surg* 1998;124:1251-1258.
81. Gillenwater A, Jacob R, Richards-Kortum R. Fluorescence spectroscopy: A technique with potential to improve the early detection of aerodigestive tract neoplasia. *Head Neck* 1998;20:556-562.
82. Schantz SP, Kolli V, Savage HE, Yu G, Shah JP, Harris DE, Katz A, Alfano RR, Huvos AG. *In vivo* native cellular fluorescence and histological characteristics of head and neck cancer. *Clin Cancer Res* 1998;4:1177-1182.
83. Heintzelman DL, Utzinger U, Fuchs H, Zuluaga A, Gossage K, Gillenwater AM, Jacob R, Kemp B, Richards-Kortum RR. Optimal excitation wavelengths for *in vivo* detection of oral neoplasia using fluorescence spectroscopy. *Photochem Photobiol* 2000;72:103-113.
84. Muller MG, Valdez TA, Georgakoudi I, Backman V, Fuentes C, Kabani S, Laver N, Wang Z, Boone CW, Dasari RR, Shapshay SM, Feld MS. Spectroscopic detection and evaluation of morphologic and biochemical changes in early human oral carcinoma. *Cancer* 2003;97:1681-1692.
85. Ingrams DR, Dhingra JK, Roy K, Perrault DF Jr, Bottrill ID, Kabani S, Rebeiz EE, Pankratov MM, Shapshay SM, Manoharan R, Itzkan I, Feld MS. Autofluorescence characteristics of oral mucosa. *Head Neck* 1997;19:27-32.
86. Inaguma M, Hashimoto K. Porphyrin-like fluorescence in oral cancer: *In vivo* fluorescence spectral characterization of lesions by use of a near-ultraviolet excited autofluorescence diagnosis system and separation of fluorescent extracts by capillary electrophoresis. *Cancer* 1999;86:2201-2211.
87. Kulapaditharom B, Boonkitticharoen V. Performance characteristics of fluorescence endoscopy in detection of head and neck cancers. *Ann Otol Rhinol Laryngol* 2001;110:45-52.
88. de Veld DC, Skurichina M, Witjes MJ, Duin RP, Sterenberg HJ, Roodenburg JL. Autofluorescence and diffuse reflectance spectroscopy for oral oncology. *Lasers Surg Med* 2005;36:356-364.
89. de Veld DC, Bakker Schut TC, Skurichina M, Witjes MJ, Van der Wal JE, Roodenburg JL, Sterenberg HJ. Autofluorescence and Raman microspectroscopy of tissue sections of oral lesions. *Lasers Med Sci* 2005;19:203-209.
90. de Veld DC, Witjes MJ, Sterenberg HJ, Roodenburg JL. The status of *in vivo* autofluorescence spectroscopy and imaging for oral oncology. *Oral Oncol* 2005;41:117-131.
91. Svistun E, Alizadeh-Naderi R, El-Naggar A, Jacob R, Gillenwater A, Richards-Kortum R. Vision enhancement system for detection of oral cavity neoplasia based on autofluorescence. *Head Neck* 2004;26:205-215.
92. Lane PM, Gilhuly T, Whitehead P, Zeng H, Poh CF, Ng S, Williams PM, Zhang L, Rosin MP, MacAulay CE. Simple device for the direct visualization of oral-cavity tissue fluorescence. *J Biomed Opt* 2006;11:024006.
93. Poh CF, Zhang L, Anderson DW, Durham JS, Williams PM, Priddy RW, Berean KW, Ng S, Tseng OL, MacAulay C, Rosin MP. Fluorescence visualization detection of field alterations in tumor margins of oral cancer patients. *Clin Cancer Res* 2006;12:6716-6722.
94. Poh CF, Ng SP, Williams PM, Zhang L, Laronde DM, Lane P, Macaulay C, Rosin MP. Direct fluorescence visualization of clinically occult high-risk oral premalignant disease using a simple hand-held device. *Head Neck* 2007;29:71-76.
95. Rosin MP, Epstein JB, Berean K, Durham S, Hay J, Cheng X, Zeng T, Huang Y, Zhang L. The use of exfoliative cell samples to map clonal genetic alterations in the oral epithelium of high-risk patients. *Cancer Res* 1997;57:5258-5260.
96. Spafford MF, Koch WM, Reed AL, Califano JA, Xu LH, Eisenberger CF, Yip L, Leong PL, Wu L, Liu SX, Jeronimo C, Westra WH, Sidransky D. Detection of head and neck squamous cell carcinoma among exfoliated oral mucosal cells by microsatellite analysis. *Clin Cancer Res* 2001;7:607-612.
97. Li Y, St John MA, Zhou X, Kim Y, Sinha U, Jordan RC, Eisele D, Abemayor E, Elashoff D, Park NH, Wong DT. Salivary transcriptome diagnostics for oral cancer detection. *Clin Cancer Res* 2004;10:8442-8450.
98. Li Y, St John MA, Wong DT. RNA profiling of cell-free saliva using microarray technology. *J Dent Res* 2004;83:199-203.
99. Hu S, Li Y, Wang J, Xie Y, Tjon K, Wolinsky L, Loo RR, Loo JA, Wong DT. Human saliva proteome and transcriptome. *J Dent Res* 2006;85:1129-1133.
100. Hu S, Loo JA, Wong DT. Human saliva proteome analysis. *Ann N Y Acad Sci* 2007;1098:323-329.
101. Zimmermann BG, Park NJ, Wong DT. Genomic targets in saliva. *Ann N Y Acad Sci* 2007;1098:184-191.
102. Park NJ, Li Y, Yu T, Brinkman BM, Wong DT. Characterization of RNA in saliva. *Clin Chem* 2006;52:988-994.
103. Park NJ, Zhou X, Yu T, Brinkman BM, Zimmermann BG, Palanisamy V, Wong DT. Characterization of salivary RNA by cDNA library analysis. *Arch Oral Biol* 2007;52:30-35.
104. Wong DT. Salivary diagnostics for oral cancer. *J Calif Dent Assoc* 2006;34:303-308.

105. Rosas SL, Koch W, da Costa Carvalho MG, Wu L, Califano J, Westra W, Jen J, Sidransky D. Promoter hypermethylation patterns of p16, O6-methylguanine-DNA-methyltransferase, and death-associated protein kinase in tumors and saliva of head and neck cancer patients. *Cancer Res* 2001; 61:939-942.
106. Juusola J, Ballantyne J. Messenger RNA profiling: A prototype method to supplant conventional methods for body fluid identification. *Forensic Sci Int* 2003;135:85-96.
107. Wang J, Henry S, Yu T, Li Y, Elashoff D, Oh M, Li K-C, Wei X, Wong D. Salivary oral cancer transcriptome biomarkers (SOCTB) for clinical detection. 2006, 35th Annual Meeting AADR; (Abstr 218).
108. Franzmann EJ, Weed DT, Civantos FJ, Goodwin WJ, Bourguignon LY. A novel CD44 v3 isoform is involved in head and neck squamous cell carcinoma progression. *Otolaryngol Head Neck Surg* 2001;124:426-432.
109. Reategui EP, de Mayolo AA, Das PM, Astor FC, Singal R, Hamilton KL, Goodwin WJ, Carraway KL, Franzmann EJ. Characterization of CD44v3-containing isoforms in head and neck cancer. *Cancer Biol Ther* 2006;5:1163-1168.
110. Franzmann EJ, Reategui EP, Carraway KL, Hamilton KL, Weed DT, Goodwin WJ. Salivary soluble CD44: A potential molecular marker for head and neck cancer. *Cancer Epidemiol Biomarkers Prev* 2005;14:735-739.
111. Mager DL, Haffajee AD, Devlin PM, Norris CM, Posner MR, Goodson JM. The salivary microbiota as a diagnostic indicator of oral cancer: A descriptive, non-randomized study of cancer-free and oral squamous cell carcinoma subjects. *J Transl Med* 2005;3: 27.
112. Dhingra JK, Zhang X, McMillan K, Kabani S, Manoharan R, Itzkan I, Feld MS, Shapshay SM. Diagnosis of head and neck precancerous lesions in an animal model using fluorescence spectroscopy. *Laryngoscope* 1998;108 (4 Pt 1): 471-475.
113. Wang CY, Tsai T, Chen HC, Chang SC, Chen CT, Chiang CP. Autofluorescence spectroscopy for *in vivo* diagnosis of DMBA-induced hamster buccal pouch pre-cancers and cancers. *J Oral Pathol Med* 2003;32:18-24.
114. Zheng W, Soo KC, Sivanandan R, Olivo M. Detection of neoplasms in the oral cavity by digitized endoscopic imaging of 5-aminolevulinic acid-induced protoporphyrin IX fluorescence. *Int J Oncol* 2002;21:763-768.
115. Leunig A, Betz CS, Baumgartner R, Grevers G, Issing WJ. Initial experience in the treatment of oral leukoplakia with high-dose vitamin A and follow-up 5-aminolevulinic acid induced protoporphyrin IX fluorescence. *Eur Arch Otorhinolaryngol* 2000;257:327-331.
116. Leunig A, Betz CS, Heinrich P, Janda P, Baumgartner R. Fluorescence staining of oral and laryngeal cancer after application of 5-aminolevulinic acid. *Laryngorhinootologie* 2002;81:807-814. (In German).
117. Leunig A, Betz CS, Mehlmann M, Stepp H, Arbogast S, Grevers G, Baumgartner R. A pilot series demonstrating fluorescence staining of laryngeal papilloma using 5-aminolevulinic acid. *Laryngoscope* 2000; 110:1783-1785.
118. Leunig A, Betz CS, Mehlmann M, Stepp H, Arbogast S, Grevers G, Baumgartner R. Detection of squamous cell carcinoma of the oral cavity by imaging 5-aminolevulinic acid-induced protoporphyrin IX fluorescence. *Laryngoscope* 2000;110:78-83.
119. Mehlmann M, Betz CS, Stepp H, Arbogast S, Baumgartner R, Grevers G, Leunig A. Fluorescence staining of laryngeal neoplasms after topical application of 5-aminolevulinic acid: Preliminary results. *Lasers Surg Med* 1999;25:414-420.
120. Jiang C, Wang C, Chiang C. Oral cancer detection in fluorescent image by color image fusion. *Conf Proc IEEE Eng Med Biol Soc* 2004;2:1260-1262.
121. Majumder SK, Ghosh N, Gupta PK. Relevance vector machine for optical diagnosis of cancer. *Lasers Surg Med* 2005;36:323-333.
122. Majumder SK, Ghosh N, Gupta PK. Support vector machine for optical diagnosis of cancer. *J Biomed Opt* 2005;10:024034.
123. Majumder SK, Ghosh N, Kataria S, Gupta PK. Nonlinear pattern recognition for laser-induced fluorescence diagnosis of cancer. *Lasers Surg Med* 2003;33:48-56.
124. Sharwani A, Jerjes W, Salih V, MacRobert AJ, El-Maaytah M, Khalil HS, Hopper C. Fluorescence spectroscopy combined with 5-aminolevulinic acid-induced protoporphyrin IX fluorescence in detecting oral premalignancy. *J Photochem Photobiol B* 2006;83:27-33.
125. Jerjes W, Swinson B, Johnson KS, Thomas GJ, Hopper C. Assessment of bony resection margins in oral cancer using elastic scattering spectroscopy: A study on archival material. *Arch Oral Biol* 2005;50:361-366.
126. Jerjes W, Swinson B, Pickard D, Thomas GJ, Hopper C. Detection of cervical intranodal metastasis in oral cancer using elastic scattering spectroscopy. *Oral Oncol* 2004;40:673-678.
127. Sharwani A, Jerjes W, Salih V, Swinson B, Bigio JJ, El-Maaytah M, Hopper C. Assessment of oral premalignancy using elastic scattering spectroscopy. *Oral Oncol* 2006;42:343-349.
128. Oliveira AP, Bitar RA, Silveira L, Zângaro RA, Martin AA. Near-infrared Raman spectroscopy for oral carcinoma diagnosis. *Photomed Laser Surg* 2006;24:348-353.
129. Cox BT, Arridge SR, Kostli KP, Beard PC. Two-dimensional quantitative photoacoustic image reconstruction of absorption distributions in scattering media by use of a simple iterative method. *Appl Opt* 2006; 45:1866-1875.
130. Laufer J, Elwell C, Delpy D, Beard P. *In vitro* measurements of absolute blood oxygen saturation using pulsed near-infrared photoacoustic spectroscopy: Accuracy and resolution. *Phys Med Biol* 2005;50:4409-4428.
131. Beard PC. Two-dimensional ultrasound receive array using an angle-tuned Fabry-Perot polymer film sensor for transducer field characterization and transmission ultrasound imaging. *IEEE Trans Ultrason Ferroelectr Freq Control* 2005;52:1002-1012.
132. Kostli KP, Beard PC. Two-dimensional photoacoustic imaging by use of Fourier-transform image reconstruction and a detector with an anisotropic response. *Appl Opt* 2003;42:1899-1908.
133. Brown E, McKee T, diTomaso E, Pluen A, Seed B, Boucher Y, Jain RK. Dynamic imaging of collagen and its modulation in tumors *in vivo* using second-harmonic generation. *Nat Med* 2003;9:796-800.
134. Lindeboom JA, Mathura KR, Ince C. Orthogonal polarization spectral (OPS) imaging and topographical characteristics of oral squamous cell carcinoma. *Oral Oncol* 2006;42:581-585.
135. Ridgway JM, Armstrong WB, Guo S, Mahmood U, Su J, Jackson RP, Shibuya T, Crumley RL, Gu M, Chen Z, Wong BJ. *In vivo* optical coherence tomography of the human oral cavity and oropharynx. *Arch Otolaryngol Head Neck Surg* 2006;132:1074-1081.
136. Wilder-Smith P, Jung WG, Brenner M, Osann K, Beydoun H, Messadi D, Chen Z. *In vivo* optical coherence tomography for the diagnosis of oral malignancy. *Lasers Surg Med* 2004;35:269-275.
137. Fitzgerald AJ, Wallace VP, Jimenez-Linan M, Bobrow L, Pye RJ, Purushotham AD, Amone DD. Terahertz pulsed imaging of human breast tumors. *Radiology* 2006;239:533-540.
138. Pickwell E, Cole BE, Fitzgerald AJ, Pepper M, Wallace VP. *In vivo* study of human skin using pulsed terahertz radiation. *Phys Med Biol* 2004;49:1595-1607.
139. Pickwell E, Fitzgerald AJ, Cole BE, Taday PF, Pye RJ, Ha T, Pepper M, Wallace VP. Simulating the response of terahertz radiation to basal cell carcinoma using *ex vivo* spectroscopy measurements. *J Biomed Opt* 2005;10:064021.
140. Wallace VP, Fitzgerald AJ, Shankar S, Flanagan N, Pye R, Cluff J, Amone DD. Terahertz pulsed imaging of basal cell carcinoma *ex vivo* and *in vivo*. *Br J Dermatol* 2004;151:424-432.
141. Wallace VP, Taday PF, Fitzgerald AJ, Woodward RM, Cluff J, Pye RJ, Amone DD. Terahertz pulsed imaging and spectroscopy for biomedical and pharmaceutical applications. *Faraday Discuss* 2004;126:255-263; 303-311.
142. Woodward RM, Cole BE, Wallace VP, Pye RJ, Amone DD, Linfield EH, Pepper M. Terahertz pulse imaging in reflection geometry of human skin cancer and skin tissue. *Phys Med Biol* 2002;47:3853-3863.
143. Woodward RM, Wallace VP, Pye RJ, Cole BE, Amone DD, Linfield EH, Pepper M. Terahertz pulse imaging of *ex vivo* basal cell carcinoma. *J Invest Dermatol* 2003;120:72-78.