

Use of ultrasonography for the diagnosis of temporomandibular joint disorders: A review

MARCELLO MELIS, DMD, RPHARM, SIMONA SECCI, MD & CAROLINE CENEVIZ, DDS, MS

ABSTRACT: Purpose: To evaluate the reliability of ultrasonography in the diagnosis of temporomandibular joint (TMJ) disorders. **Methods:** A review of the literature was performed, searching for all articles published between 1966 and 2006, and examining the ones which met the selection criteria. **Results:** Ultrasonography sensitivity ranged from 13-100% for the evaluation of disc displacement (DD), from 70.6-83.9% for the evaluation of joint effusion (JE), and from 70-94% for the evaluation of condylar erosion (CE). Specificity ranged from 62-100% for the evaluation of DD, from 73.7-100% for the evaluation of JE, and from 20-100% for the evaluation of CE. Accuracy ranged from 51.5-100% for the evaluation of DD, from 72.2-95% for the evaluation of JE, and from 67-94% for the evaluation of CE. (*Am J Dent* 2007;20:73-78).

CLINICAL SIGNIFICANCE: Ultrasonography is a noninvasive and inexpensive diagnostic procedure that can be suggested for the evaluation of TMJ disorders, with particular accuracy in the detection of disc displacement and joint effusion. Limitations are especially related to the scarce accessibility of the medial part of the TMJ structures, and the need for trained and calibrated operators.

✉: Dr. Marcello Melis, Via Grosseto, 1, 09125 Cagliari, Italy. E-✉: marcellomelis01@libero.it

Introduction

Many diagnostic means have been indicated for the diagnosis of temporomandibular disorders (TMD), including electrodiagnostic tests such as jaw-tracking devices, electromyography, thermography, sonography for the evaluation of joint sounds, vibration analysis, and several imaging techniques.¹⁻⁴ Such imaging techniques consist of plain and panoramic radiography, conventional and computerized tomography (CT) scan, arthrography, magnetic resonance (MRI) and radionuclide imaging.^{1-3,5-13} All the methods mentioned above are always considered adjunctive procedures for the diagnosis of TMD, because anamnesis and clinical evaluation of the patient, in most cases, are sufficient to make a correct diagnosis.^{1-3,10,14,15}

However, the use of ultrasonography for the diagnosis of temporomandibular joint (TMJ) disorders is uncommon, although several reports have been found in the literature¹⁶⁻³⁸ suggesting evident advantages of the utilization of such procedure that is inexpensive and noninvasive compared to the other imaging tools habitually used, such as MRI, arthrography and CT scan.

The present review evaluated the diagnostic reliability of ultrasonography in the diagnosis of TMJ disorders.

Ultrasonographic technique

The principle of ultrasonography is based on the fact that ultrasonic sound waves emitted by a device (transducer), travel through the tissue against which they are aimed, and are partly reflected on transiting through dissimilar anatomical structures. The reflected sound waves are then read by the same emitting device, and translated into images.³⁹

The TMJ region consists of diverse structures that reflect sound waves differently. Bone tissue, represented by the head of the condyle and the articular eminence, is generally hypoechoic (low reflection of sound waves) and appears black in ultrasonography images, however the margin of the bone is hyperechoic (high reflection of sound waves) and appears white

in ultrasonography images. Connective tissue, represented by the joint capsule and the retrodiscal tissue, and muscular tissue, represented by the lateral pterygoid and masseter muscles, are isoechoic (intermediate reflection of sound waves) and appear heterogeneously grey in ultrasonography images. However the surface of the joint capsule, as well as the surface of the muscles, highly reflect the sound waves generating a hyperechoic (white) line. Empty space and water, like the superior and inferior joint spaces, are hypoechoic and appear black in ultrasonography images, however, these anatomic cavities are virtual because the opposing surfaces are in contact, and usually not detectable, unless effusion is present.⁴⁰ The articular disc, similarly to all major ligaments, consists of dense fibrous tissue, but its appearance in ultrasonography images is controversial. It has been reported to be hyperechoic,^{18,30,35,36} hypoechoic,^{20,21,23,33,34,37,38} isoechoic,²⁴ and hypoechoic to isoechoic,^{25,27} probably for the presence of different structural, morphological and positional abnormalities in the patients examined. By ultrasonography it is also possible to identify sites of inflammation by detecting the presence of articular effusion.⁴⁰

The difficulty of picturing the TMJ using ultrasounds depends on the limited accessibility of the deep structures, especially the disc, due to absorption of the sound waves by the lateral portion of the head of the condyle and the zygomatic process of the temporal bone. In fact, the transducer that emits and receives the sound waves is usually located over these structures, on the skin in front of the tragus.

Literature review

Inclusion criteria: A review of the literature was performed searching for all the articles published from 1966 to 2006 on the use of ultrasonography, alone or compared with other diagnostic procedures, in the diagnosis of TMJ disorders. The initial year of 1966 was chosen because most electronic indexing starts in that year; in addition, no articles were found on the topic before 1991.¹⁶ The key words “temporomandibular joint disorders” on one side, and “ultrasonography” and “echo-

Table. Summary of the studies reviewed.

Authors	Transducer	Positioning	Gold standard	Disc	Target	Results			
						Static CM	Static OM	Dynamic CM	Dynamic OM
Emshoff R et al 1997 ¹⁸	7.5 MHz	Horizontal	MRI	Hyperechoic	DD	SE: 50% SP: 71% AC: 54.6%	SE: 13% SP: 74% AC: 55.6%	SE: 39% SP: 100% AC: 51.5%	SE: 13% SP: 95% AC: 70.4%
Landes C et al 2000 ²⁰	5-10 MHz	Horizontal/ Vertical	MRI	Hypoechoic	DDWR	SE: 90% SP: 85.7% AC: 87.5%			
Jank S et al 2001 ²¹	12 MHz	Vertical/ horizontal	MRI	Hypoechoic	DD	SE: 78% SP: 78% AC: 78%	SE: 61% SP: 88% AC: 77%		
Emshoff R et al 2002 ²³	12 MHz	Horizontal	MRI	Hypoechoic	DD	SE: 90% SP: 94% AC: 91%	SE: 96% SP: 91% AC: 93%		
Emshoff R et al 2002 ²⁴	12 MHz	Vertical	MRI	Isoechoic	DD	SE: 80% SP: 87% AC: 82%	SE: 68% SP: 93% AC: 82%		
Emshoff R et al 2002 ²⁵	12 MHz	Vertical	MRI	Hypoechoic to isoechoic	ID-DDWR-DDWOR			SE: 93-82-83% SP: 98-95-96% AC: 95-92-90%	
Uysal S et al 2002 ²⁶	7.5 MHz	Horizontal	MRI		DDWR - DDWOR	SE: 100-100% SP: 100-100% AC: 100-100%			
Emshoff R et al 2003 ²⁷	12-12.5 MHz	Vertical	MRI	Hypoechoic to isoechoic	DC-DC+ DDWOR - DDWOR			SE: 83-88-95% SP: 63-79-91% AC: 67-80-93%	
Brandlmaier I et al 2003 ²⁸	12-12.5 MHz	60° from horizontal	MRI		DD-DDWR-DDWOR	SE: 93-76-63% SP: 77-78-89% AC: 87-77-83%	SE: 63%* SP: 89%* AC: 80%*		
Brandlmaier I et al 2003 ²⁹	12-12.5 MHz	Vertical	MRI		DC	SE: 87% SP: 20% AC: 79%			
Tognini F et al 2003 ³⁰	8-15 MHz	Horizontal/ vertical	MRI	Hyperechoic with a hypoechoic halo	JE	SE: 75.6% SP: 76.6% AC: 76.1%			
Melchiorre D et al 2003 ³³	7.5 MHz		MRI	Hypoechoic	JE-DR	SE: 70.6-69.6% SP: 75-30% AC: 72.2-57.6%			
Jank S et al 2005 ³⁴			MRI	Hypoechoic	DC-JE-DD		SE: 94-81-92% SP: 100-100-92% AC: 94-95-92%	SE: 86%* SP: 91%* AC: 90%*	
Tognini F et al 2005 ³⁵	8-20 MHz	Vertical	MRI	Hyperechoic with a hypoechoic halo	DD	SE: 65.8% SP: 80.4% AC: 73.1%			
Manfredini D et al 2005 ³⁶	8-20 MHz	Vertical	MRI	Hyperechoic with a hypoechoic halo	JE-DD-DC	SE: 85.1-56.7-67.3% SP: 66.7-73.7-26.3% AC: 79.4-66.2-55.9%			
Landes CA et al 2006 ³⁷	8-12.5 MHz	Horizontal**	MRI	Hypoechoic	DC-DDe	SE: 70/64% SP: 76/73% AC: 75/71%			
Landes CA et al 2006 ³⁸	8-12.5 MHz	Horizontal**	MRI	Hypoechoic	DD	SE: 62% SP: 62% AC: 62%	SE: 43% SP: 85% AC: 77%		

CM: Closed mouth; OM: Open mouth; DC: Degenerative changes; DD: Disc displacement; DDe: Disc degeneration; DR: Disc-related diagnosis (including displacement, structural and morphological changes); JE: Joint effusion; SE: Sensitivity; SP: Specificity; AC: Accuracy.

* Values referred to disc displacement.

** 3-D Ultrasonography.

graphy” on the other side were combined in a Ovid Medline and Pubmed search. The abstracts which appeared to fulfill the initial selection criteria were selected, and the original articles were obtained. Their references were then hand-searched looking for other possible missing articles, and a total of 36 articles were found. Stricter selection criteria were then applied. Since in none of the studies the calculation of sample size and randomization of the subjects was performed, in only one of them²⁴ intra- and inter-observer reliability was calculated, in one of them¹⁸ it was specified that the operator was blind to clinical diagnosis of TMD, and in none of them was it specified

that the patients were blind to the diagnosis, we decided not to include these limitations in the selection criteria. The following selection criteria were set: (1) Presence of MRI as gold standard for the TMJ diagnosis; (2) Calculation of sensitivity, specificity, accuracy or presence of data allowing such calculation; (3) ultrasonography diagnosis blind to the MRI diagnosis.

The selection of the articles was performed by two different reviewers independently (MM and SS). When discrepancies occurred between them, the criterion for the inclusion of the paper was discussed until agreement was reached. The reviewers were not blinded to the identity of the study authors.

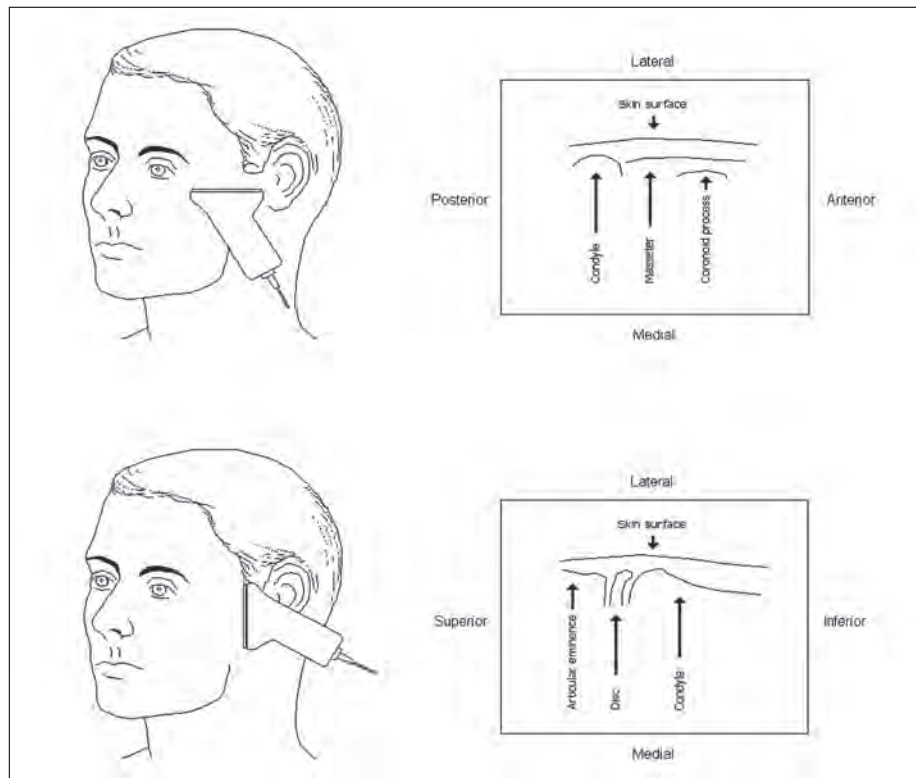


Figure. Positioning of the transducer and consequent visualization of the temporomandibular joint (TMJ). **A.** Horizontal positioning, transverse image of the TMJ. **B.** Vertical positioning, coronal/sagittal image of the TMJ (depending on the angulation of the transducer).

Only 17 articles fulfilled all criteria and were included in the review.^{18,20,21,23-30,33-38}

The Table summarizes the main features of the studies examined.

Results

Emshoff *et al*¹⁸ were the first to compare ultrasonography diagnosis with that of MRI of the TMJs. They used a 7 MHz transducer positioned horizontally; consequently, the images obtained were in the transverse plane (Fig. A), and evaluated the TMJs by both static and dynamic ultrasonography. They reported a low sensitivity of the procedure, but a high specificity, especially in the dynamic evaluation (95-100%), which can suggest ultrasonography in the identification of normal disc position in patients with signs and symptoms of TMJ disorders. Another study¹⁹ described a way of positioning the transducer that would allow a better visualization of the head of the condyle and the disc that are usually hidden by the temporal bone. The authors suggested rotating the transducer 60 degrees from the horizontal plane, following the plane of the articular eminence, and tilting it 5-10 degrees from the line perpendicular to the sagittal plane in order to have access from above the zygomatic process of the temporal bone.

Landes *et al*²⁰ suggested the use of ultrasonography for measurement of mandibular range of motion obtaining 83% agreement with axiographic results. They also reached values of sensitivity, specificity and accuracy close to 90% for the diagnosis of disc displacement with reduction (DDWR), compared to MRI, using both horizontal and vertical positioning of the transducer (Fig. A, B).

In 2001, Jank *et al*²¹ introduced the use of a high resolution

transducer of 12 MHz to better visualize the TMJ structures. Differently from most of the previous reports, where the disc was described as hyperechoic, the authors considered it as a hypoechoic structure in the glenoid fossa surrounded by a hyperechoic rim. Their results, comparing ultrasonography diagnoses with diagnoses based on MRI, achieved a sensitivity, specificity and accuracy at closed-mouth position of 78%, and a sensitivity, specificity and accuracy of 61%, 88% and 77%, respectively, at maximum-mouth opening position. The values of sensitivity obtained in those studies^{20,21} were higher than those obtained previously,¹⁸ and allowed a more reliable detection of TMJ internal derangements (ID).

Another study by Emshoff *et al*²³ improved the values of sensitivity, specificity and accuracy of the exam to 90-96%, 94-91%, and 91-93% respectively, at closed-mouth and maximum-mouth opening positions. The authors stressed the concept that importance should be given to the positive predictive value (PPV) that was equal to 97%, and that expresses how much the presence of the finding is predictive of a true abnormality, even in case of lower sensitivity and specificity. Again, the use of a high resolution transducer seems to be relevant for an accurate diagnosis. Others^{41,42} questioned the interpretation of the ultrasonography images, arguing that the hypoechoic structure identified as the articular disc is probably the TMJ capsule or joint effusion. The point raised underlines the difficulty of interpreting ultrasonography images. In the same year, Emshoff *et al*²⁴ published a larger study where for the first time intra-observer and inter-observer variability was evaluated. Although sensitivity, specificity and diagnostic accuracy of the procedure were lower than the ones reported in the previous article, 80-68%, 87-93%, and 82-82% respectively, at mouth closed and

open, intra-observer agreement was 93% at mouth closed and 88% at maximum opening, and inter-observer agreement was 89% at mouth closed and 84% at maximum opening. Those values were considered well within acceptable limits, together with the fact that a low sensitivity is balanced by a high specificity. This implicates a very small number of false positives, thereby decreasing the risk of unnecessary treatment. More precise outcomes can also be achieved using dynamic ultrasonography instead of static ultrasonography, as shown by Emshoff *et al.*^{25,27} Static views of the TMJ are more difficult to interpret because ultrasonography images are blurred and not clear; conversely, dynamic images allow identification of anatomic structures more easily. Sensitivity was 93% for ID, 82% for DDWR, 83-93% for disc displacements without reduction (DDWOR), specificity can be as high as 98% for ID, 95% for DDWR, 91-96% for DDWOR, accuracy can be as high as 95% for ID, 92% for DDWR, 90-93% for DDWOR. Detection of condylar erosion was less reliable with levels of sensitivity, specificity and accuracy of 83%, 63% and 67% respectively. Although using a 7.5 Mhz transducer, the highest performance was obtained by Uysal *et al.*²⁶ who found perfect agreement between MRI and ultrasonography diagnoses. The results of Brandlmaier *et al.*^{28,29} confirmed the diagnostic value of ultrasonography to detect the absence, but not the presence of ID of the TMJ, because of its high specificity and lower sensitivity for the diagnosis of DDWR and DDWOR, and the low reliability of the procedure in the diagnosis of osteoarthrosis, in agreement with a previous study.²⁷

Evaluation of intra-articular effusion was reported to have a diagnostic accuracy ranging from 72.2-95%, with values of sensitivity ranging from 70.6-85.1%, and values of specificity ranging from 66.7-100%.^{30,33,34,36} Tognini *et al.*³⁰ assumed the presence of joint effusion when the distance between the lateral pole of the condyle and the lateral part of the articular capsule was greater than 3 mm, while Manfredini *et al.*³⁶ in another study, used a cut-off value of 2 mm. As we could expect, reducing such value increased sensitivity, but significantly reduced the specificity of the exam. Melchiorre *et al.*³³ described levels of sensitivity, specificity and accuracy for the diagnosis of disc-related diagnoses (including displacement, structural and morphological changes) that were very low: 69.6%, 30% and 57.6% respectively, despite the fact that they performed a static and dynamic assessment of the TMJ. Probably, the use of a 12-12.5 MHz high-resolution transducer, instead of the 7.5 MHz transducer utilized, would have improved the results. In fact, reports by Jank *et al.*³⁴ using the high-resolution transducer, reached very high levels of accuracy both in the evaluation of disc displacement (DD), joint effusion and degenerative changes (DC) of the TMJ. Other recent studies^{35,36} reported significant difficulty locating the articular disc in the open-mouth position, therefore evaluation of DD was carried out in the closed-mouth position only. Levels of sensitivity and diagnostic accuracy were not very high, however specificity reached the value of 73.7%-80.4% for DD. Low levels of reliability were confirmed for the detection of DC of the condyle.³⁶

A different approach was suggested by Landes *et al.*^{37,38} using a 3-D ultrasonography for the diagnosis of DC of the condyle and the articular eminence, disc degeneration, and DD.

The opinion of the authors of that study was that 3-D reconstruction of ultrasonography images allows a complete picture of the condyle, not a single transection in the transverse, frontal, or near-sagittal plane. Furthermore, interpretation of the images is easier because different cuts can be placed within the scan volume. In spite of these considerations, the values of sensitivity, specificity and diagnostic accuracy of the procedure for DD (62-62-62%, respectively, in the closed-mouth position, 43-85-77%, respectively, in the open-mouth position), and DC of the condyle and the articular eminence (70-76-75%, respectively) were not higher than the average of the ones obtained in the previous studies examined where 2-D ultrasonography was used. Differently from the opinion of others,^{35,36} disc position was more accurately detected in the open-mouth position (Table).

Discussion

The present review revealed a growing interest in the development of a standardized examination of the TMJ using ultrasonography. In fact, if acceptable levels of diagnostic accuracy are reached, the advantages of such a simple and inexpensive diagnostic procedure are relevant from a clinical point of view.

Differences were seen among the articles regarding the technique used for examination of the TMJ. First of all, a diverse equipment was utilized, especially the transducers had frequencies ranging from 5 MHz (low resolution)²⁰ to 20 MHz (high resolution)^{35,36} as a consequence of the technological evolution. The position of the transducer also varied from horizontal (parallel to the zygomatic arc)^{18,20,21,23,26,30} to vertical (parallel to the ramus of the mandible),^{20,21,24,25,27,29,30,35} giving a different image of the TMJ in a transverse or a coronal/sagittal plane (Figure, Table). In reality, the planes of the images are rarely true transverse, coronal or sagittal, but almost always inclined, because the transducer is tilted during the examination in order to achieve a better visualization of the different components of the TMJ, especially the disc. This consideration does not apply in 3-D ultrasonography, where the TMJ can be evaluated in different planes within the scan volume.

Another major difference that was found among the articles selected was the appearance of the disc in ultrasonographic images. Some authors described the disc as hyperechoic,^{18,30,35,36} while others reported a hypoechoic,^{20,21,23,33,34,37,38} an isoechoic,²⁴ or a hypoechoic to isoechoic appearance,^{25,27} probably for the presence of different structural, morphological and positional abnormalities in the patients examined (Table). These are likely to be the reasons of the diverse levels of sensitivity, specificity and accuracy obtained in the studies. Nonetheless, overall values are generally high, especially for the diagnosis of DD, in spite of the various techniques used in the assessment of the patients' TMJs (Table).

The lowest values are usually referred to the sensitivity of the examination, while specificity tends to be high. This can originate false negative results, but can rarely induce the clinician to make an erroneous diagnosis of ID of the TMJ in absence of pathology; and this is fundamental in order to avoid unnecessary treatment. In fact, although TMJ disorders are common pathological conditions in the population, with 40-75% of people showing at least one sign of joint dysfunction

and 33% of people reporting at least one symptom, only 3.6-7% of these subjects are in need of treatment.¹ In addition, such disorders are not life threatening and serious conditions, but frequently self-limiting.^{1,43,44} For these reasons, it is more important for an appropriate diagnostic exam to be able to accurately identify subjects without pathology (high specificity), than for the exam to identify subjects with the disease (high sensitivity), especially in a contest where clinical signs and symptoms are usually sufficient to make the diagnosis.

Limits to the use of ultrasonography for the diagnosis of TMJ disorders are related to the difficulty in the visualization of the articular disc, that is allowed only through the small gap between the zygomatic process of the temporal bone (above) and the head of the condyle (below). It is very difficult to obtain satisfactory images especially when the condyle rotates and translates from the mouth-closed position to the mouth-open position. It is necessary to constantly adjust the position of the transducer to better visualize the disc. Furthermore, only the lateral part of the TMJ can be reached, while the medial part remains hidden by the mentioned structures. As a consequence, medial displacements of the disc are likely to be overlooked.

Another limit can be represented by the difficulty of interpreting the images which are blurred and not clear; therefore the need of well trained and calibrated operators can be important to obtain reliable results. In fact, most of the studies selected for the review were performed by only four study groups: University of Innsbruck (Austria),^{18,21,23-25,27-29,34} University of Frankfurt (Germany),^{20,37,38} Hacettepe University of Ankara (Turkey),²⁶ and University of Pisa (Italy),^{30,33,35,36} therefore results obtained by other non-trained operators might not be as accurate and reliable as the ones highlighted in this review. In only one article²⁴ intra-observer and inter-observer agreement was calculated, having two different investigators interpreting separately a set of 200 images in 50 patients randomly selected twice, blind to the results of the previous interpretation, and to the interpretation of the other investigator. Intra-observer agreement for the detection of disc position ranged between 87-93%, inter-observer agreement ranged between 82-90%. These results are well within acceptable limits and suggest high reliability of the procedure when performed by trained and calibrated operators, in spite of the difficulty of interpreting ultrasonography images. Nonetheless, more controlled studies are needed to evaluate intra-observer and inter-observer agreement especially among more than two operators, in order to include ultrasonography in the common exams for the diagnosis of TMJ disorders.

Another limitation is also the quality of the studies selected for the review. As we already mentioned, none of the studies included calculation of sample size and randomization of the subjects, in only one of them²⁴ intra- and inter-observer reliability was calculated, in another one¹⁸ it was specified that the operator was blind to clinical diagnosis of TMD, and in none of them it was specified that the patients were blind to the diagnosis. We chose not to include these limitations in the selection criteria because we could not find a sufficient number of studies with those characteristics; however, this limits the quality of the review, and the reliability of the results.

In light of the results shown in this review, ultrasonography can be used to investigate TMJ pathology, particularly for the

diagnosis of DD and joint effusion. It seems less accurate and reliable to evaluate the presence of osteoarthritis. The highest performances seem to be related to the use of high-resolution transducers (12-12.5-20 MHz),^{23,25,27,35,36-38} (although in one case 100% accuracy was obtained using a 7.5 Mhz transducer²⁶) and to the use of both static and dynamic ultrasonography.^{25,27}

Despite the possibility of obtaining images of the TMJ in different planes, the use of 3-D ultrasonography does not seem, at the moment, to increase the reliability of the exam.

It must also be considered that ultrasonography diagnoses were compared to MRI diagnoses, which is, to date, the most reliable method of investigation for TMJ disorders. Still, accuracy of MRI is not 100%, if referred to cryosectional morphology of the TMJ. Using a 1.5 T imager, accuracy was calculated to be 95%, sensitivity 90% and specificity 100% for the evaluation of disc position, when both sagittal and coronal views were considered.⁴⁵ Therefore, the values reported in the Table might be slightly different if they could be compared to the real occurrence of the disease.

Conclusions

Ultrasonography is a noninvasive and inexpensive diagnostic procedure that has been shown to be accurate for the diagnosis of articular DD and joint effusion. For this reason it can be suggested for the evaluation of TMJ disorders. However, since very diverse techniques have been reported, further research is needed to standardize the exam, in order to avoid or reduce the limits related to the scarce accessibility of the TMJ structures.

Dr. Melis is in private practice, Cagliari, Italy, and is Adjunct Clinical Instructor, Craniofacial Pain Center, Tufts University, School of Dental Medicine, Boston, Massachusetts, USA. Dr. Secci is in private practice, Cagliari, Italy. Dr. Ceneviz is Assistant Professor, Craniofacial Pain Center, Tufts University, School of Dental Medicine, Boston, Massachusetts, USA.

References

- Okeson JP. Assessment of orofacial pain disorders. In: Okeson JP. *Orofacial pain: Guidelines for assessment, diagnosis, and management*. Chicago: Quintessence, 1996; 19-44.
- Dworkin SF, LeResche L. Research diagnostic criteria for temporomandibular disorders: Review, examinations and specifications, critique. *J Craniomandib Disord* 1992; 6:301-355.
- Okeson JP. History and examination for temporomandibular disorders. In: Okeson JP. *Management of temporomandibular disorders and occlusion*. 4th Ed. St. Louis: Mosby, 1998; 234-309.
- Gelb M. Diagnostic tests. In: Kaplan AS, Assael LA. *Temporomandibular disorders, diagnosis and treatment*. Philadelphia: W.B. Saunders, 1991; 371-385.
- Kaplan AS. Plain, tomographic, and panoramic radiography and radionuclide imaging. In: Kaplan AS, Assael LA. *Temporomandibular disorders, diagnosis and treatment*. Philadelphia: W.B. Saunders, 1991; 312-336.
- Danielson PA. Arthrography. In: Kaplan AS, Assael LA. *Temporomandibular disorders, diagnosis and treatment*. Philadelphia: W.B. Saunders, 1991; 337-352.
- Milbauer DL. Magnetic resonance imaging and computerized tomography. In: Kaplan AS, Assael LA. *Temporomandibular disorders, diagnosis and treatment*. Philadelphia: W.B. Saunders, 1991; 353-370.
- Christiansen EL, Thompson JR. Radiographic evaluation of the TMJ. In: Pertes RA, Gross SG. *Clinical management of temporomandibular disorders and orofacial pain*. Chicago: Quintessence, 1995; 161-174.
- Westesson PL. Magnetic resonance imaging of the temporomandibular joint. In: Pertes RA, Gross SG. *Clinical management of temporomandibular disorders and orofacial pain*. Chicago: Quintessence, 1995; 175-196.
- Pharoah MJ. The prescription of diagnostic images for temporomandibular joint disorders. *J Orofac Pain* 1999; 13:251-254.
- Brooks SL, Brand JW, Gibbs SJ, Hollender L, Lurie AG, Omnell KA, Westesson PL, White SC. Imaging of the temporomandibular joint: A

- position paper of the American Academy of Oral and Maxillofacial Radiology. *Oral Surg Oral Med Oral Pathol* 1997; 83:609-618.
12. Liedberg J, Panmekiate S, Petersson A, Rohlin M. Evidence-based evaluation of three imaging methods for the temporomandibular disc. *Dentomaxillofac Radiol* 1996; 25:234-241.
 13. Zarb GA, Carlsson GE. Temporomandibular disorders: Osteoarthritis. *J Orofac Pain* 1999; 13:295-306.
 14. Austin DG, Pertes RA. Examination of the TMD patient. In: Pertes RA, Gross SG. *Clinical management of temporomandibular disorders and orofacial pain*. Chicago: Quintessence, 1995; 123-160.
 15. Tenenbaum HC, Freeman BV, Psutka DJ, Baker GI. Temporomandibular disorders: Disc displacements. *J Orofac Pain* 1999; 13:285-290.
 16. Nabeih YB, Speculand B. Ultrasonography as a diagnostic aid in temporomandibular joint dysfunction. A preliminary investigation. *Int J Oral Maxillofac Surg* 1991; 20:182-186.
 17. Stefanoff V, Hausamen JE, Van den Berghe P. Ultrasound imaging of the TMJ disc in asymptomatic volunteers. Preliminary report. *J Craniomaxillofac Surg* 1992; 20:337-340.
 18. Emshoff R, Bertram S, Rudisch A, Gassner R. The diagnostic value of ultrasonography to determine the temporomandibular joint disk position. *Oral Surg Oral Med Oral Pathol* 1997; 84:688-696.
 19. Motoyoshi M, Kamijo K, Numata K, Namura S. Ultrasonic imaging of the temporomandibular joint: A clinical trial for diagnosis of internal derangement. *J Oral Sci* 1998; 40:89-94.
 20. Landes C, Walendzik H, Klein C. Sonography of the temporomandibular joint from 60 examinations and comparison with MRI and axiography. *J Craniomaxillofac Surg* 2000; 28:352-361.
 21. Jank S, Rudisch A, Bodner G, Brandlmaier I, Gerhard S, Emshoff R. High-resolution ultrasonography of the TMJ: helpful diagnostic approach for patients with TMJ disorders? *J Craniomaxillofac Surg* 2001; 29:366-371.
 22. Hayashi T, Ito J, Koyama J, Yamada K. The accuracy of sonography for evaluation of internal derangement of the temporomandibular joint in asymptomatic elementary school children: Comparison with MR and CT. *Am J Neuroradiol* 2001; 22:728-734.
 23. Emshoff R, Jank S, Rudisch A, Bodner G. Are high-resolution ultrasonographic signs of disc displacement valid? *J Oral Maxillofac Surg* 2002; 60:623-628; discussion 628-629.
 24. Emshoff R, Jank S, Rudisch A, Walch C, Bodner G. Error patterns and observer variations in the high-resolution ultrasonography imaging evaluation of the disk position of the temporomandibular joint. *Oral Surg Oral Med Oral Pathol* 2002; 93:369-375.
 25. Emshoff R, Jank S, Bertram S, Rudisch A, Bodner G. Disk displacement of the temporomandibular joint: Sonography versus MR imaging. *Am J Roentgenol* 2002; 178:1557-1562.
 26. Uysal S, Kansu H, Akhan O, Kansu O. Comparison of ultrasonography with magnetic resonance imaging in the diagnosis of temporomandibular joint internal derangements: A preliminary investigation. *Oral Surg Oral Med Oral Pathol* 2002; 94:115-121.
 27. Emshoff R, Brandlmaier I, Bodner G, Rudisch A. Condylar erosion and disc displacement: Detection with high-resolution ultrasonography. *J Oral Maxillofac Surg* 2003; 61:877-881.
 28. Brandlmaier I, Rudisch A, Bodner G, Bertram S, Emshoff R. Temporomandibular joint internal derangement: Detection with 12.5 MHz ultrasonography. *J Oral Rehabil* 2003; 30:796-801.
 29. Brandlmaier I, Bertram S, Rudisch A, Bodner G, Emshoff R. Temporomandibular joint osteoarthritis diagnosed with high resolution ultrasonography versus magnetic resonance imaging: How reliable is high resolution ultrasonography? *J Oral Rehabil* 2003; 30:812-817.
 30. Tognini F, Manfredini D, Melchiorre D, Zampa V, Bosco M. Ultrasonographic vs magnetic resonance imaging findings of temporomandibular joint effusion. *Minerva Stomatol* 2003; 52:365-370.
 31. Manfredini D, Tognini F, Melchiorre D, Zampa V, Bosco M. Ultrasound assessment of increased capsular width as a predictor of temporomandibular joint effusion. *Dentomaxillofac Radiol* 2003; 32:359-364.
 32. Manfredini D, Tognini F, Melchiorre D, Cantini E, Bosco M. The role of ultrasonography in the diagnosis of temporomandibular joint disc displacement and intra-articular effusion. *Minerva Stomatol* 2003; 52:93-100.
 33. Melchiorre D, Calderazzi A, Maddali Bongi S, Cristofani R, Bazzichi L, Eligi C, Maresca M, Ciompi M. A comparison of ultrasonography and magnetic resonance imaging in the evaluation of temporomandibular joint involvement in rheumatoid arthritis and psoriatic arthritis. *Rheumatology* 2003; 42:673-676.
 34. Jank S, Emshoff R, Norer B, Missmann M, Nicasi A, Strobl H, Gassner R, Rudisch A, Bodner G. Diagnostic quality of dynamic high-resolution ultrasonography of the TMJ. A pilot study. *Int J Oral Maxillofac Surg* 2005; 34:132-137.
 35. Tognini F, Manfredini D, Melchiorre D, Bosco M. Comparison of ultrasonography and magnetic resonance imaging in the evaluation of temporomandibular joint disc displacement. *J Oral Rehabil* 2005; 32:248-253.
 36. Manfredini D, Tognini F, Melchiorre D, Bazzichi L, Bosco M. Ultrasonography of the temporomandibular joint: Comparison of findings in patients with rheumatic diseases and temporomandibular disorders. A preliminary report. *Oral Surg Oral Med Oral Pathol* 2005; 100:481-485.
 37. Landes CA, Goral WA, Mack MG, Sader R. 3-D sonography for diagnosis of osteoarthritis and disk degeneration of the temporomandibular joint, compared with MRI. *Ultrasound Med Biol* 2006; 32:627-632.
 38. Landes CA, Goral WA, Sader R, Mack MG. 3-D sonography for diagnosis of disk dislocation of the temporomandibular joint compared with MRI. *Ultrasound Med Biol* 2006; 32:633-639.
 39. Merritt CRB. Physics of ultrasound. In: Rumack CM, Wilson SR, Charboneau JW. *Diagnostic ultrasound*. St. Louis: Mosby, 1998; 3-55.
 40. Middleton WD, Kurtz AB, Hertzberg BS. Extremities. In: Middleton WD, Kurtz AB, Hertzberg BS. *Ultrasound: The requisites*. St. Louis: Mosby, 2004; 278-301.
 41. Westesson PL. Are high-resolution ultrasonographic signs of disc displacement valid? [Discussion] *J Oral Maxillofac Surg* 2002; 60:628-629.
 42. Elias FM, Birman EG, Jorge WA, Homsí C. Ultrasonography of the temporomandibular joint: Where is the disc? [Letter to the Editor] *J Oral Maxillofac Surg* 2002; 60:1381.
 43. Nickerson JW, Boering G. Natural course of osteoarthritis as it relates to internal derangement of the temporomandibular joint. *Oral Maxillofac Surg Clin North Am* 1989; 1:1-19.
 44. Sato S, Goto S, Kawamura H, Motegi K. The natural course of nonreducing disc displacement of the TMJ: Relationship of clinical findings at initial visit to outcome after 12 months without treatment. *J Orofac Pain* 1997; 11:315-320.
 45. Tasaki MM, Westesson PL. Temporomandibular joint: Diagnostic accuracy with sagittal and coronal MR imaging. *Radiology* 1993; 186:723-729.