

The incidence of pulp healing defects with direct capping materials

PETER E. MURRAY, PHD & FRANKLIN GARCÍA-GODOY, DDS, MS

ABSTRACT: *Purpose:* To (1) study the injury and healing activity of the pulp tissue to calcium hydroxide [Ca(OH)₂], resin composite (RC) and resin-modified glass-ionomer (RMGI) materials when used as direct pulp capping agents, and (2) compare the incidence of healing defects between these materials. *Methods:* 135 Class V pulp exposed cavities were prepared in non-human primate teeth. Direct pulp capping was conducted over 6 to 730 days with hard set Ca(OH)₂, RMGI and CR materials. Healing defects recorded were: (1) bacterial leakage with McKays stain; (2) operative debris including dentin fragments and particles of capping material; (3) pulpal inflammatory activity according to FDI standards; (4) area and absence of dentin bridge formation; and (5) presence of tunnel defects in bridge. Statistical analysis was evaluated using ANOVA. *Results:* The capping materials were associated with varying levels of pulp healing defects, including tunnel defects (P= 0.0001); operative debris (P= 0.0001); pulpal inflammatory cell activity (P= 0.0073) and bacterial leakage (P= 0.0260). Other healing defects, and the area of dentin bridge were not influenced by capping materials (P> 0.05). (*Am J Dent* 2006;19: 171-177).

CLINICAL SIGNIFICANCE: Pulp healing defects have some relationship with treatment failure, but the general lack of information on material-pulp interactions remains problematic. Resin composite and resin-modified glass-ionomer materials can optimize healing following pulp capping, because they appear to reduce the number of defects in comparison with Ca(OH)₂.

✉: Dr. Peter. E. Murray, Department of Endodontics, College of Dental Medicine, Nova Southeastern University, 3200 South University Drive, Fort Lauderdale, FL 33328, USA. E-✉: petemurr@nova.edu

Introduction

The prognosis of direct pulp capped teeth is much reduced in comparison with indirect pulp capped teeth. The success of the direct pulp capping of teeth is 37% after 5 years and 13% after 10 years.¹ This result compares with an 86% rate of success over 10 years, when teeth containing a hard carious lesion have been indirectly pulp capped.² A study of the prognosis of direct *versus* indirect pulp capping on primary teeth also showed that indirect capped teeth will have better longevity.³ These studies demonstrate the importance of avoiding pulp exposure and placing indirect restorations to optimize the success of treatment. Whenever excavation of dentin caries results in a carious pulp exposure, pulpotomy is necessary to save the tooth.⁴ Nevertheless, there are many situations where the pulp has become exposed traumatically and accidentally. In these situations, the prognosis for pulp capping may be favorable, but controversy remains about the incidence of pulp healing defects between different types of capping materials.

Factors that may influence pulp healing are:

Bacterial leakage - The prevention of bacterial leakage into cavity preparations is an important goal in treatment planning and will contribute to the longevity of cavity restorations. Bacterial leakage complications include inflammation, post-operative sensitivity, marginal discoloration, recurrent caries and eventual need for endodontic therapy.^{5,6}

Operative debris - This includes dentin fragments, particles of capping material and/or globules of adhesive. These particles are associated with bacteria, pulpal inflammation and necrosis.⁷

Pulpal inflammatory cell activity - In severe forms, this is associated with hypersensitivity and treatment failure. It appears to be caused by bacterial leakage more so than material cytotoxicity.⁸

Absence of dentin bridge formation - The deposition of a dentin bridge is associated with pulp vitality and pulp protection. The absence of dentin bridging is associated with compromised healing.⁹

Tunnel defects in dentin bridge - These defects allow the leakage of bacteria into pulp tissue and are a measure of the quality or sealing of the dentin bridge.¹⁰ Consequently the incidence and severity of these defects influence pulp healing and treatment outcomes.

Seventy years ago, Herman¹¹ published a treatise on calcium hydroxide [Ca(OH)₂] for direct pulp capping. Since then, many dentists have come to regard it as their preferred pulp capping material. The high pH Ca(OH)₂ provides bactericidal activity, and is associated with increased dentin bridge formation.^{12,13} However, this material is compromised by unstable physical properties which allow particles of capping material¹⁴ including dentin chips⁷ to migrate into pulp tissue and complicate pulp healing.

Research into bonding agents for attachment of resins to tooth structure was started in the early 1950s.¹⁵ Over time, resin composite (RC) materials have gradually become widely accepted for indirect pulp capping treatments, however, their use for direct pulp capping has stimulated much controversy. The absence of protective dentin between the pulp and capping material sensitizes the pulp to the potentially toxic chemical activity of the dental material.¹⁶ Direct pulp capping with CR has been associated with pulpal inflammation from acid etching,¹⁷ migration of adhesive globules and operative debris into the pulp,^{18,19} postoperative sensitivity,²⁰ incomplete dentin bridge formation,^{21,22} possible injury from the temperature increase created during light polymerization²³ and claims of disastrous pulp necrosis.²⁴ Furthermore, polymerization shrinkage and contraction stresses, often produce less than perfect results.²⁵ Nevertheless, many primate^{10,26-28} and

Table 1. Pulp capping materials.

Product name (Material type)	Time period elapsed (days)			
	Short	Medium	Long	Total
Life ^c (calcium hydroxide)	8	10	22	42
Vitremer + Vitrebond ^d (resin-modified glass-ionomer)	10	16	10	36
One step + Duel-cure ^e Liner Bond II ^f + Clearfil AP-X ^f All Bond ^f + Aelitefil ^f (resin composites)	12	15	30	57

clinical studies^{29,30} have shown that CR may be as effective if not more effective, than Ca(OH)₂ at minimizing healing defects. Consequently, the advantages of direct pulp capping with CR *versus* Ca(OH)₂ remain controversial.

Resin modified glass-ionomer (RMGI) is widely used for temporary indirect pulp capping. Among the advantages are an anti-cariogenic activity,³¹ ability to remineralize dentin³² and stable physical characteristics, albeit with low fracture resistance.³³ Some advantages of RMGI may make for the ideal pulp capping material, but information is scarce about the effects of RMGI direct pulp capping.³⁴ However, when RMGI has been used to restore deep indirect cavity preparations, some underlying pulp injury was observed^{35,36} and consequently the degree of underlying injury and effects on healing remain uncertain. Information about the pulp responses to RMGI when used as a direct pulp capping material is limited.

Continuing evidence of a high proportion of restored teeth showing symptoms requiring pulpotomy or extraction,³⁷ together with evidence showing that only 40% of all types of restorations are new, with 60% being replacements for failures³⁸ suggests restorative treatment modalities are not fully optimized. Consequently it is important to evaluate healing defects with various pulp capping materials. Understanding how the defects are created will allow their avoidance, and selection of materials to optimize pulp capping outcomes. More than 2000 primate teeth have been prepared for histological evaluation, but few studies reported on pulp capping materials.^{10,26,27,34} For this study, all the teeth pulp capped were histometrically evaluated using contemporary criteria by an independent investigator, and none of this data has previously been published. This study (1) evaluated the injury and healing activity of the pulp tissue to Ca(OH)₂, CR and RMGI materials when used as direct pulp capping agents; and (2) compared the incidence of healing defects between these materials.

Materials and Methods

This is a retrospective histological investigation of an archive of teeth based at the University of Alabama at Birmingham, Alabama. One hundred and thirty five sound teeth were used from eight adult *Rhesus macaca* monkeys. The animals were approximately 4-5 years of age at the start of dental treatment. The teeth were relatively free from wear and erosion. The third molars had erupted. The animals were cared for according to ethical and animal use guidelines of the University Animal Review procedures. Prior to operative procedures, each animal was tranquilized and sedated. Briefly, each monkey was tranquilized with an intramuscular injection of 10mg/kg of ketamine hydrochloride^a (100 mg/mL). Deeper sedation was achieved with an intramuscular injection of rompun.^b Teeth

Table 2. Histological criteria for assessment of pulp reactions.

Histologic assessment	Histologic criteria
Pulpitis: None	The pulp contained few inflammatory cells, or an absence of inflammatory cells.
Pulpitis: Slight	The pulp had localized inflammatory cell lesions predominated by polymorphonuclear leucocytes, or mononuclear mononuclear lymphocytes associated with the site of pulp exposure.
Pulpitis: Moderate	The pulp had polymorphonuclear leucocyte lesions involving more than one-third of the coronal pulp.
Pulpitis: Severe	Following chronic inflammatory cell activity, the pulp tissue is largely necrotic.
Dentin bridge area	The area of tertiary dentin secreted by odontoblast-like cells at the site of pulp exposure.
Tunnel defect	A discontinuity of complete dentin bridge formation across the site of pulp exposure, sometimes containing cells and called tissue tracts.
Operative debris area	The area of dentin chips, particles of restorative material and globules of adhesive observed after direct pulp capping.
Bacterial leakage	The presence of McKays stained bacteria within the restoration margins and/or pulp tissue.

were polished with pumice paste to remove plaque and calculus. Saliva was controlled by high-speed evacuation and quadrants of teeth were isolated with sterile cotton rolls. Pulp exposed Class V cavities were prepared with a #330 carbide bur at ultra-high speed under water spray coolant. The size of pulp exposure was limited to the width of a #330 carbide bur. Hemorrhage was controlled with a damp cotton pellet with 5.25% solution of sodium hypochlorite (NaOCl), held in place for 30 seconds. The cavity was rinsed with sterile saline and gently air dispersed. The cavities were immediately capped with the test materials. The standardized methods and procedures used in this study are congruent with those described else-where.^{6,10,26,27,34}

All materials were placed according to their manufacturers instructions following International Organization for Standardization Technical Report 7405 usage guidelines,³⁹ however the evaluation guidelines of 5± 2 days and 70± 5 days were expanded to cover short; 6-22 days; medium 23-96 days; or long 97-730 days, terms. Forty-two exposed pulps were direct pulp capped with Ca(OH)₂ (Table 1). All Ca(OH)₂ cavities were sealed at the cavosurface margin with zinc oxide eugenol. Thirty-six cavities were restored with RMGI and 57 pulps were direct pulp capped with CR (Table 1).

Serial sections of 7µm thickness, stained with hematoxylin and eosin, were examined by light microscopy, and histological analysis was conducted, using the techniques described elsewhere.^{40,41} The area of dentin bridges were measured at x100 magnification using a reticule to provide an estimate of bridge size. Within each dentin bridge, the area of operative debris was also measured using a reticule at x400 magnification. The dentin fragments and particles of material were often closely associated and difficult to separate, this is why both are measured as operative debris.^{40,41} The pulp exposure width, axial cavity floor width and cavity wall depth were also measured in each tooth. Within the dentin bridge, the absence or presence of tunnel defects was observed at x400 magnification. For the purposes of this study, a tunnel defect is a discontinuity in the structure of complete dentin bridge formation. A summary of the histologic criteria is shown in Table 2.

The inflammatory response of each pulp was categorized

Table 3. Correlation between the use of different pulp capping materials and the histological observation of pulp healing defects.

Difference between pulp capping materials and the following variables:	F value	ANOVA P-value
Incidence of tunnel defects	25.971	0.0001
Operative debris area	17.797	0.0001
Incidence of slight, moderate or severe pulpitis	5.136	0.0073
Incidence of bacterial leakage	3.769	0.0260
Dentin bridge area	2.284	0.1066

as none, slight, moderate or severe, according to published criteria.^{6,10,26,27,34} The categories of pulp inflammation are summarized in Table 2. Bacterial contamination of each restoration was assessed using McKay's stain⁴² to detect the presence of gram positive and negative microorganisms. Data were analyzed using analysis of variance (ANOVA) statistical procedures, at a confidence level of 95% (STATview software[®]). These procedures are reportedly among the most versatile and conservative of the multiple comparison tests.⁴³

Results

A statistical analysis of the raw data found no significant difference (ANOVA or Chi square, $P > 0.05$) between the restorative products within the $\text{Ca}(\text{OH})_2$, RMGI, or CR groups of dental materials, therefore, this study compared differences between the $\text{Ca}(\text{OH})_2$, RMGI, or CR groups of dental materials as follows:

Tunnel defects - The most statistically significant difference between pulp capping materials and their effect on pulpal activity was the presence of tunnel defects (Table 3). Tunnel defects were closely correlated to pulp capping materials and the area of operative debris (Fig. 1). The frequency of tunnel defects was 82% with $\text{Ca}(\text{OH})_2$ and 42% and 0% with RMGI and CR respectively (Fig. 2). Furthermore, tunnel defects were closely correlated to the area of operative debris and dentin bridge area, while in the absence of tunnel defects these two variables are not correlated (Fig. 3). This suggests that the probability of tunnel defects in dentin bridges increases with both an increase in operative debris area and dentin bridge area associated with pulp capping materials.

Operative debris - The second most statistically significant difference between CR, RMGI and $\text{Ca}(\text{OH})_2$ capped pulps appeared to be the area of operative debris incorporated in underlying dentin bridges (Table 3). The greatest area of operative debris was observed in pulps capped with $\text{Ca}(\text{OH})_2$ and the least area was observed following pulp capping with CR (Fig. 1). The area of operative debris observed in pulps capped with RMGI was intermediate to the other capping materials (Fig. 1). The frequency of operative debris was found to vary between materials, with 77%, 57% and 29% of pulps capped with $\text{Ca}(\text{OH})_2$, RMGI and CR containing these pulp capping defects (Fig. 2).

Pulp inflammation - The third most statistically significant difference between pulp capping materials was the category of pulpal inflammatory cell activity (Table 3). In the absence of bacterial leakage, pulpal inflammatory cell activity was found to vary between none and slight categories (Fig. 4). In the presence of bacterial leakage, $\text{Ca}(\text{OH})_2$ was associated with more moderate categories of pulpal inflammation in com-

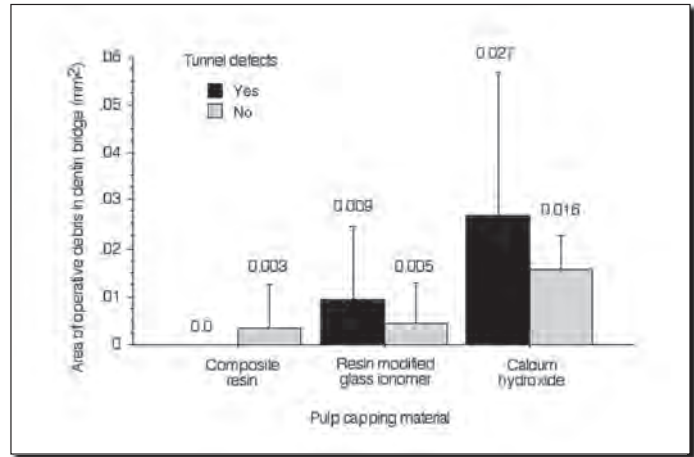


Fig. 1. Operative debris and tunnel defects.

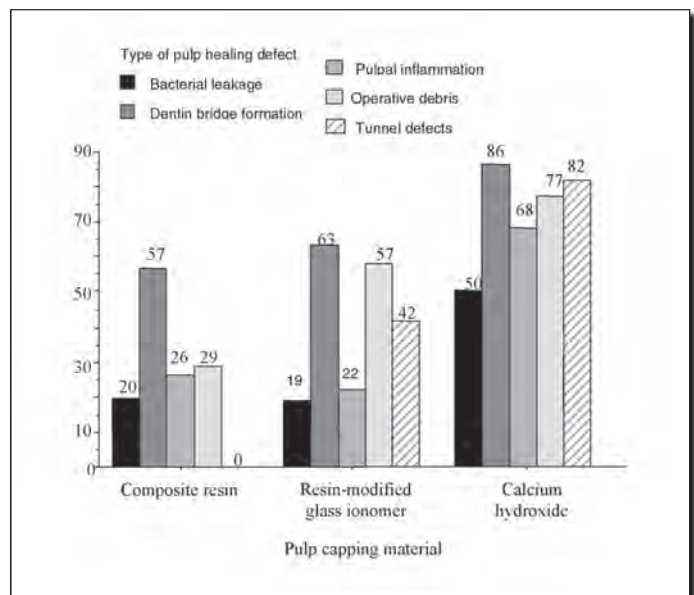


Fig. 2. Frequency of pulp healing defects.

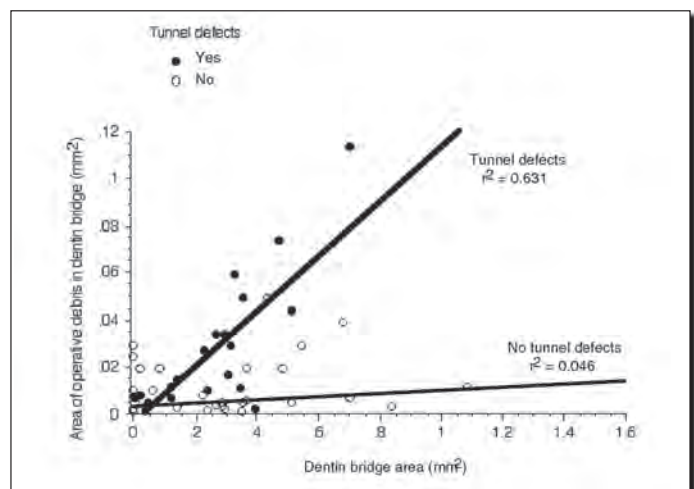


Fig. 3. Dentin bridge area and operative debris.

parison with the slight category associated with RMGI and CR pulp capping materials (Fig. 4). The frequency of capped pulps showing any slight, moderate or severe category of inflammation was greatest with $\text{Ca}(\text{OH})_2$ and much less following capping with RMGI and CR, 68%, 22% and 26% respectively (Fig. 2).

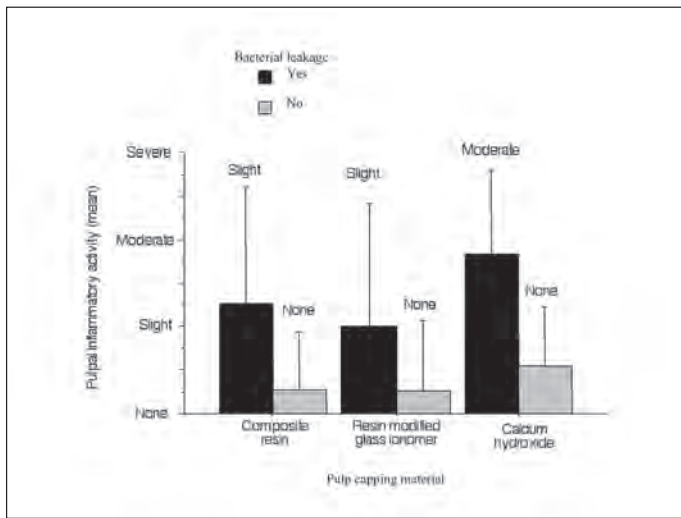


Fig. 4. Pulp inflammatory activity and bacterial leakage.

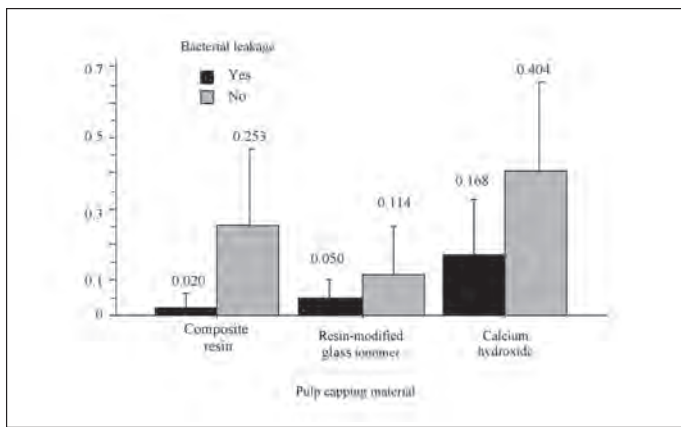


Fig. 5. Dentin bridge area and bacterial leakage.




Fig. 6. Photograph of dentin bridge containing healing defects.

Bacterial leakage - The leakage of bacteria into capped pulps appeared to vary according to the type of material used for pulp capping (Table 3). The frequency of bacterial leakage observed in $\text{Ca}(\text{OH})_2$ capped pulps was 50%; much lower frequencies of 20% and 19% were observed following pulp capping with CR or RMGI (Fig. 2). The presence of bacteria appeared to stimulate pulpal inflammatory cell activity (Fig. 4) and reduce the area of dentin bridge formation (Fig. 5) irrespective of the material used for pulp capping.

Dentin bridge - The largest dentin bridges were generally observed in $\text{Ca}(\text{OH})_2$ capped pulps (Fig. 5). In comparison, the mean area of dentin bridge formation with CR and RMGI was reduced by -37.4% and -71.8% respectively in the absence of bacterial leakage (Fig. 5). However, despite these differences in dentin bridge area between capping materials,

bacteria, pulpal inflammatory activity and operative debris appeared to have a more powerful effect on dentin bridge area, because the difference between pulp capping materials was not statistically significant at the $P=0.05$ level (Table 3; $P=0.1066$). The presence of operative debris (ANOVA, $P=0.0003$) (Figs. 1, 3) or the presence of bacteria (ANOVA, $P=0.0031$) (Fig. 5) had a greater influence on the area of dentin bridge, than pulp inflammatory activity (ANOVA, $P=0.0157$) (Fig. 4). The frequency of dentin bridges observed following pulp capping with $\text{Ca}(\text{OH})_2$ was 86%, while 63% and 57% of pulps capped with RMGI or CR were associated with dentin bridge formation (Fig. 2). However, no dentin bridges were observed following the short pulp capping time interval. Consequently the formation of dentin bridge appears to be the summation of the area of operative debris, bacteria, pulp capping material and the time elapsed following capping. Often operative debris containing dentin chips, fragments of capping material and tunnel defects was observed in close association (Fig. 6).

Pulp exposure width and cavity dimensions - No statistical differences at the $P=0.05$ significance were found between the types of capping materials and the width of pulp exposure, or any of the Class V cavity dimensions.

Discussion

Previous investigations of pulp capping activity have been criticized for being short term, some lasting between 3 and 60 days,^{19,21,44,45} the ISO guidelines only specify 5 ± 2 days and 70 ± 5 days.³⁹ But healing complications may take years to manifest and consequently, pulpal healing was investigated over 2 years. This extended timescale allowed observation of completed pulpal healing and dentin bridge formation. Nevertheless, caution is required when interpreting these results, because it is not possible to directly correlate healing defects with the long-term mechanical failure and leakage aspects of capping materials, which may be observed in patients over decades. Clinical study of these aspects would be required, but in most countries ethical laws limit this type of experimentation. Consequently, this study provides new assessments of pulp capping treatments by measuring the frequency and severity of pulp healing defects associated with $\text{Ca}(\text{OH})_2$, RMGI and CR. It is postulated that by minimizing the frequency and severity of healing defects, the prognosis of pulp capping treatments will increase.

The methods used in this study to examine pulpal healing have shown that defects can be measured quantitatively. These measurements can provide potentially useful information on pulp healing in response to capping materials. Qualitative methods are the most frequently used means of examining pulp reactions to the effects of dental materials, but these evaluations always contain an element of subjectivity.⁴⁶ The use of a histomorphometric approach to this investigation permitted the collection of precise pulpal measurements, which allowed statistical analysis using ANOVA statistics. These statistics provided the accuracy and analytical procedures for detecting correlations between variables that are not possible with categorical approaches.⁴³ The numbers of teeth in each of the material test groups ranged between 36 for RMGI, 42 for $\text{Ca}(\text{OH})_2$, and 57 for CR, the total number of

135 teeth appeared to be sufficient to investigate the incidence of pulp capping defects.

Following pulp exposure, the occurrence of operative debris including dentin chips, can be considered to be an advantage because they stimulate dentin bridge formation.⁴⁷ While this study has confirmed a direct correlation between the area of operative debris and increased dentin bridging, there does not appear to be any benefits associated with operative debris, only healing complications. Much emphasis is placed on the presence and size of dentin bridge formation and this is often regarded as a sign of successful pulp healing. Dentin bridging is observed in 90% of human capped pulps following exposure.⁴⁸ The size of the dentin bridge is important, because its size reduces the pulp chamber volume⁴⁹ making subsequent root canal access more difficult. However, the size of the dentin bridge should not be confused with the quality of protection it provides to the remaining vital pulp tissue. The presence of operative debris disrupts bridge integrity, weakening its structure, probably through lack of continuity of dentin secretion by the odontoblastoid cells.⁵⁰ Operative debris is also associated with increased pulpal inflammatory cell activity from the persistence of globules of adhesive^{18,19} and particles of $\text{Ca}(\text{OH})_2$.¹⁴ The operative debris may be contaminated with bacteria, which can infiltrate the pulp tissue to stimulate immune reactions, in severe cases progressing to pulp necrosis and inhibition of dentin bridge formation.¹⁸ Sometimes dentin bridging is incomplete⁵¹ and this is a problem, because a bridge needs to be effective at sealing the pulp exposure. Frequently, operative debris has migrated away from the site of exposure deep into pulp tissue. The stimulation of bridging around this migrated debris is unlikely to be beneficial for pulp exposure protection, and more likely to impair otherwise healthy tissue. These problems explain why operative debris is not beneficial for the purpose of pulp protection, which is the major role of dentin bridging.⁴⁸ The findings of this present study indicate that healing defects associated with operative debris are most associated with $\text{Ca}(\text{OH})_2$ rather than RMGI or CR pulp capping treatments, because of the 77% of pulps affected *versus* 57% and 29% respectively. Although it should be appreciated that fragments of dentin are unavoidably created during cavity preparation, the migration of some of these fragments into pulp tissue may be minimized. Consequently, the cleansing of excessive dentin chips from the site of pulp exposure along with subjacent blood clots, to promote pulpal healing and improve the subsequent integrity of dentin bridge formation,⁵² appears to be good advice. However, all the cavities were prepared and cleansed with a standardized procedure and this cannot explain the large variation between materials of from 29% to 77%. Clearly most of this difference reflects the migration of particles of capping material. $\text{Ca}(\text{OH})_2$ materials dissolve over time⁵³ depending on their sample dimensions and composition.⁵⁴ By comparison, RMGI and CR materials appear chemically and physically bio-stable,^{55,56} explaining the reduced level of operative debris. This evidence suggests that the long term disintegration and migration of $\text{Ca}(\text{OH})_2$ particles into the pulp does not make it an ideal pulp capping material

The presence of tunnel defects in dentin bridges is poten-

tially more problematic than the presence of operative debris, although both are closely correlated. This is because tunnel defects destroy the sealing ability of the bridge, allowing the migration of $\text{Ca}(\text{OH})_2$ particles, resin globules and the leakage of bacteria.^{10,12,14} In cases where the bacteria have progressed into pulp tissue, severe inflammation and necrosis can be observed.^{5,57} Ideally, to avoid these healing complications, the creation of tunnel defects should be minimized. The reason for the correlation between operative debris and tunnel defects requires further investigation, but the presence of operative debris may impede the ability of odontoblastoid cells to uniformly secrete a dentin bridge. Following pulp capping with $\text{Ca}(\text{OH})_2$, 82% of the dentin bridges were found to contain some tunnel defects, 42% of tunnel defects were observed in RMGI capped dentin bridges, while no tunnel defects were observed in bridges capped with CR. This observation suggests that tunnel defects can be avoided by minimizing the operative debris associated with cavity preparation and cleansing the exposure, prior to using a CR capping material. The interactions between capping materials and the odontoblastoid cells have not been well studied. But there is evidence to suggest some heterogeneity in dentin bridge structure caused by the type and rate of dentin secretion by odontoblastoid cells.^{19,21} Consequently, the ability of the capping material to modulate the odontoblastoid cell secretion of dentin bridges is of some interest for stimulating pulpal repair, especially when the prognosis of capping is poor. $\text{Ca}(\text{OH})_2$ has been claimed to uniquely stimulate dentin bridging in comparison with other capping materials.¹² However, in agreement with some previous observations, dentin bridging did not appear to be uniquely stimulated by $\text{Ca}(\text{OH})_2$ materials.^{13,56}

Unresolved pulp inflammation is associated with postoperative sensitivity, discoloration, failure of pulp healing and dentin bridge formation as well as the eventual need for endodontic treatment.^{5,57} In agreement with earlier investigations, the majority of pulp inflammation was associated with bacterial leakage,^{6,48} however, in the absence of bacterial leakage, pulpal inflammatory activity in pulps capped with $\text{Ca}(\text{OH})_2$, CR and RMGI was similar. Nevertheless, large differences in the ability of the materials to prevent bacterial leakage were observed. RMGI appeared to seal and adhere with pulp exposures more completely (19%) than CR (20%) or $\text{Ca}(\text{OH})_2$ (50%). These findings are in agreement with reports suggesting that RMGI has excellent sealing, antibacterial and anticariogenic characteristics due to fluoride release.^{5,32} CR materials have good sealing properties, due to recent improvements in adhesive bonding with cavity walls.⁵⁸ In addition, reports suggest that $\text{Ca}(\text{OH})_2$ restorations become infected because of their inability to provide a complete seal with cavity walls, a lack of long-term bacteriocidal activity, and unstable physical properties.⁵⁹

Unfortunately, it is not possible to isolate the pulp injury created by capping procedures from the effects of capping materials. The skill and experience of the operator is extremely important for guiding treatment outcomes⁶⁰ and differences in handling techniques may influence both the technical quality and clinical performance of the capping materials. This is one explanation of why pulp capping with

CR has proved to be divisive among researchers. The second reason for divergent reports on pulp capping with CR, is that although some adhesive systems provide a satisfactory performance for restoring non-pulp exposed restorations, the chemical toxicity of the adhesive system is not compatible with direct pulp capping.⁶¹ The variation between adhesive systems may further explain why some materials are claimed to be suitable for direct pulp capping while others are not. A third explanation for differences in observations between pulp capping materials is that case selection is extremely important for influencing the clinical success of pulp capping. For example, capped pulps showing inflammatory activity are more difficult to heal successfully in comparison to capped pulps with no treatment or disease history.⁶² Although many pulp capping reviews and studies are supportive of CR materials,^{56,63-66} some insist that CR pulp capping is associated with persistent inflammatory reactions and delayed dentin bridging.^{67,68} CR direct pulp capping has also been reported to delay nerve regeneration.^{69,70} These concerns prevent unqualified recommendation of pulp capping with CR materials, and clearly more research is required to optimize the placement and technique sensitivity of these materials to surpass the empirical clinical success of Ca(OH)₂. RMGI has not been well studied for pulp capping and more investigation is required, but it was not associated with high rates of healing defects and may be beneficial for pulp capping in caries-prone patients.

This study has shown that pulp capping with RMGI or CR can provide a superior performance to Ca(OH)₂ in terms of minimizing healing defects. However, much more investigation of pulp capping failure is required to fully understand the defects responsible, and to modify the use and type of capping materials to increase the success of pulp capping. The success of pulp capping may be strongly influenced by the age and condition of teeth prior to capping, such as the history of caries lesions, previous restorations, size of pulp chamber/canal system, and open apex. But information is limited on the effects of these variables. Ca(OH)₂ and amalgam are chemically-simple pulp capping materials with limited scope for technological development. While further improvements to adhesive systems, including bioactive molecules to mediate pulp repair,^{71,72} antibacterial activity,⁷³ improved sealing and bond strengths⁷⁴ and caries prevention⁷⁵ will likely have some impact on the gaining acceptance of CR materials for all types of pulp capping situations.

- a. Parke-Davis, Detroit, MI, USA.
- b. Haver Lockhart, Bayvet Division, Shawnee, KS, USA.
- c. Kerr, Romulus, MI, USA.
- d. 3M ESPE Dental Products, St Paul, MN, USA.
- e. Bisco Co, Schaumburg, IL, USA.
- f. Kuraray Co., Osaka, Japan.
- g. SAS Inc. Chicago, IL, USA.

Dr. Murray is Associate Professor, Department of Endodontics and Director of Biologic Research; Dr. García-Godoy is Professor, Associate Dean for Research, and Director of the Bioscience Research Center, College of Dental Medicine, Nova Southeastern University, Fort Lauderdale, FL, USA.

References

1. Barthel CR, Rosenkranz B, Leuenberg A, Roulet JF. Pulp capping of carious exposures: Treatment outcome after 5 and 10 years: A retrospective study. *J Endod* 2000;26:525-528.
2. Mertz-Fairhurst EJ, Curtis JW, Ergle JW, Rueggeberg FA, Adair SM. Ultraconservative and cariostatic sealed restorations: Results at year 10. *J Am Dent Assoc* 1998;129:55-66.
3. Farooq NS, Coll JA, Kuwabara A, Shelton P. Success rates of formocresol pulpotomy and indirect pulp therapy in the treatment of deep dentinal caries in primary teeth. *Pediat Dent* 2000;22:278-286.
4. Swift EJ Jr, Trope M. Treatment options for the exposed vital pulp. *Pract Perio Aesthet Dent* 1999;11:735-739.
5. Bergenholtz G, Cox CF, Loesche WJ, Syed SA. Bacterial leakage around dental restorations: Its effect on the dental pulp. *J Oral Pathol* 1982;11:439-450.
6. Cox CF. Evaluation and treatment of bacterial microleakage. *Am J Dent* 1994;7:293-295.
7. Horsted P, El Attar K, Langeland K. Capping of monkey pulps with Dycal and a Ca-eugenol cement. *Oral Surg Oral Med Oral Pathol* 1981;52:531-553.
8. About I, Murray PE, Franquin J-C, Remusat M, Smith AJ. Pulpal inflammatory responses following non-carious Class V restorations. *Oper Dent* 2001;26:336-342.
9. Baume LJ, Holtz L. Long term clinical assessment of direct pulp capping. *Int Dent J* 1981;31:251-260.
10. Cox CF, Subay RK, Ostro E, Suzuki S, Suzuki SH. Tunnel defects in dentin bridges: Their formation following direct pulp capping. *Oper Dent* 1996;21:4-11.
11. Herman BW. Dentin obliteration after treatment with calcium. *Zahnarzt Rundschau* 1930;39:888-899 (In German).
12. Yoshida K, Yoshida N, Iwaku M. Histological observations of hard tissue barrier formation in amputated dental pulp capped with tricalcium phosphate containing hydroxide. *Endod Dental Traumatol* 1994;10:113-120.
13. Foreman PC, Barnes IE. Review of calcium hydroxide. *Int Endod J* 1990;23:283-297.
14. Walton RE, Langeland K. Migration of materials in the dental pulp of monkeys. *J Endod* 1978;4:167-177.
15. McLean JW, Kramer IRH. A clinical and pathological evaluation of a sulphonic acid activated resin for use in restorative dentistry. *Br Dent J* 1952;93:255-269.
16. Murray PE, Lumley PJ, Ross HF, Smith AJ. Tooth slice organ culture for cytotoxicity assessment of dental materials. *Biomater* 2000;21:1711-1721.
17. Retief DH, Austin JC, Fatti LP. Pulpal response to phosphoric acid. *J Oral Pathol* 1974;3:114-122.
18. Gwinnett AJ, Tay F. Early and intermediate time response of the dental pulp to an acid etch technique *in vivo*. *Am J Dent* 1998;11 (Spec Is): S35-S44.
19. Kitasako Y, Shibata S, Pereira PNR, Tagami J. Short-term dentin bridging of mechanically exposed pulps capped with adhesive resin systems. *Oper Dent* 2000;25:155-162.
20. Umemori M, Matsuya Y, Akashi A, Goto Y, Akamine A. Composite resin restoration and postoperative sensitivity: clinical follow-up in an undergraduate program. *J Dent* 2001;29:7-13.
21. Kitasako Y, Inokoshi S, Tagami J. Effects of direct resin pulp capping techniques on short-term response of mechanically exposed pulps. *J Dent* 1999;27:257-263.
22. de Souza Costa CA, Lopes DO, Nascimento AB, Teixeira HM, Fontana UF. Response of human pulps capped with a self-etching adhesive system. *Dent Mater* 2001;17:230-240.
23. Hannig M, Bott B. *In-vitro* pulp chamber temperature rise during composite resin polymerization with various light-curing sources. *Dent Mater* 1999;15:275-281.
24. Parmeijer CH, Stanley HR. The disastrous effects of the "total etch" technique in vital pulp capping in primates. *Am J Dent* 1998;11 (Spec Is): S45-S59.
25. Bergenholtz G. Evidence for bacterial causation of adverse pulpal responses in resin-based dental restorations. *Crit Rev Oral Biol Med* 2000;11:467-480.
26. Cox CF, Bergenholtz G, Fitzgerald M, Heys DR, Heys RJ, Avery JK, Baker JA. Capping of the dental pulp mechanically exposed to oral microflora. A 5 week observation of wound healing in the monkey. *J Oral Pathol* 1982;11:327-339.
27. Cox CF, Keall CL, Keall HJ, Ostro E, Bergenholtz G. Biocompatibility of surface-sealed dental materials against exposed pulps. *J Prosthet Dent* 1987;57:1-8.
28. Akimoto N, Momoi Y, Kohno A, Suzuki S, Otsuki M, Suzuki S, Cox CF. Biocompatibility of Clearfil Liner Bond 2 and Clearfil AP-X system on nonexposed and exposed primate teeth. *Quintessence Int* 1998;29:177-188.
29. Heitmann T, Unterbrink G. Direct pulp capping with a dental adhesive resin system: A pilot study. *Quintessence Int* 1995;26:765-770.
30. Gorecka V, Suliborski S, Biskupski T. Direct pulp capping with a dentin adhesive resin system in children's permanent teeth after traumatic injuries: Case reports. *Quintessence Int* 2000;31:241-248.
31. Park SH, Kim KY. The anticariogenic effect of fluoride in primer, bonding agent, and composite resin in the cavosurface enamel area. *Oper Dent*

- 1997;22:115-120.
32. Donly KJ, Segura A, Wefel JS, Hogan MM. Evaluating the effects of fluoride-releasing dental materials on adjacent interproximal caries. *J Am Dent Assoc* 1999;130:817-825.
 33. Qualtrough AJ, Cawte SG, Wilson NH. Influence of different transitional restorations on the fracture resistance of premolar teeth. *Oper Dent* 2001;26:267-272.
 34. Tarim B, Hafez AA, Cox CF. Pulpal response to a resin-modified glass-ionomer material on nonexposed and exposed monkey pulps. *Quintessence Int* 1998;29:535-542.
 35. Stanley HR. Pulpal consideration of adhesive materials. *Oper Dent* 1992;5 (Suppl 5):151-164.
 36. Murray PE, About I, Franquin J-C, Remusat M, Smith AJ. Restorative pulpal and repair responses. *J Am Dent Assoc* 2001;132:482-491.
 37. Deligeorgi V, Mjor IA, Wilson NH. An overview of reasons for the placement and replacement of restorations. *Prim Dent Care* 2001;8:5-11.
 38. Amst C, Carey J. Biotech Bodies. *Businessweek* 1998 July 42-49.
 39. ISO, 7405. *Preclinical evaluation of biocompatibility of medical devices used in dentistry; Test methods for dental materials*. Geneva, Switzerland: International Organization for Standardization; 1997.
 40. Murray PE, Lumley PJ, Hafez AA, Cox CF, Smith AJ. Preserving the vital pulp in operative dentistry: 4. Factors influencing successful pulp capping. *Dent Update* 2002;29:225-230, 232-233.
 41. Murray PE, Hafez A, Smith AJ, Cox CF. Hierarchy of pulp capping and repair activities responsible for dentin bridge formation. *Am J Dent* 2002;15:236-243.
 42. McKay GS. Gram stain modified to improve colour contrast. *J Clin Pathol* 1970; 23:191.
 43. Dawson-Saunders B, Trapp RG. *Basic and clinical biostatistics*. 2nd ed. Norwalk, Conn.: Appleton & Lange; 1994.
 44. Kitasako Y, Arakawa M, Sonoda H, Tagami J. Light and scanning electron microscopy of the inner surfaces of resins used in direct pulp capping. *Am J Dent* 1999;12:317-321.
 45. Kitasako Y, Shibata S, Arakawa M, Cox CF, Tagami J. A light and transmission microscopic study of mechanically exposed monkey pulps. *Oral Surg Oral Med Oral Pathol* 2000;89:224-230.
 46. Warfvinge J. Morphometric analysis of teeth with inflamed pulp. *J Dent Res* 1987;66:78-83.
 47. Stanley HR. Pulp capping: Conserving the dental pulp. Can it be done? Is it worth it? *Oral Surg* 1989;68:628-639.
 48. Baume LJ, Holz J. Long term clinical assessment of direct pulp capping. *Int Dent J* 1981;31:251-260.
 49. Stanley HR, Clark AE, Pameijer CH, Louw NP. Pulp capping with a modified bioglass formula (#A68 modified). *Am J Dent* 1991;14:227-232.
 50. Fitzgerald M, Chiego DJ Jr, Heys DR. Autoradiographic analysis of odontoblast replacement following pulp exposure in primate teeth. *Arch Oral Biol* 1990;35:707-715.
 51. Kitasako Y, Inokoshi S, Fujitani M, Otsuki M, Tagami J. Short-term reaction of exposed pulp beneath adhesive resins. *Oper Dent* 1998; 23:308-317.
 52. Mjor IA. Pulp-dentin biology in restorative dentistry. Part 7: The exposed pulp. *Quintessence Int* 2002;33:113-135.
 53. Akester J. Disappearing Dycal. *Br Dent J* 1979;147:369-375.
 54. Murray PE, Lumley PJ, Smith AJ, Ross HF. The influence of sample dimensions on hydroxyl ion release from calcium hydroxide products. *Endod Dent Traumatol* 2000;16:251-257.
 55. Santerre JP, Shajij L, Leung BW. Relation of dental composite formulations to their degradation and the release of hydrolyzed polymeric-resin-derived products. *Crit Rev Oral Biol Med* 2001;12:136-151.
 56. Cox CF, Suzuki S. Re-evaluating pulp protection: Calcium hydroxide liners vs. cohesive hybridization. *J Am Dent Assoc* 1994;125:823-831.
 57. Bergenholtz G. Effects of bacterial products on inflammatory reactions in the dental pulp. *Scand J Dent Res* 1982;85:122-129.
 58. Swift EJ Jr. Bonding systems for restorative materials. A comprehensive review. *Pediat Dent* 1998;20:80-84.
 59. Kopel HM. The pulp capping procedure in primary teeth "revisited". *ASDC J Dent Child* 1997;64:327-333.
 60. Cox CF, Tarim B, Kopel H, Gurel G, Hafez A. Technique sensitivity: Biological factors contributing to clinical success with various restorative materials. *Adv Dent Res* 2001;15:85-90.
 61. Hebling J, Giro EM, de Souza Costa CA. Biocompatibility of an adhesive system applied to exposed human dental pulp. *J Endod* 1999;25:676-682.
 62. Mjor IA. Pulp-dentin biology in restorative dentistry. Part 5: Clinical management and tissue changes associated with wear and trauma. *Quintessence Int* 2001;32:771-788.
 63. Schuur AHB, Gruythuysen RJM, Wesselink PR. Pulp capping with adhesive resin-based composite vs. calcium hydroxide: A review. *Endod Dent Traumatol* 2000;16:240-250.
 64. van Dijken JWV. Direct resin composite inlays/onlays: An 11-year follow up. *J Dent* 2000;28:299-306.
 65. Olmez A, Oztas N, Basak F, Sabuncuoglu B. A histopathologic study of direct pulp-capping with adhesive resins. *Oral Surg Oral Med Oral Pathol* 1998;86:98-103.
 66. Ranly DM, Garcia-Godoy F. Current and potential pulp therapies for primary and young permanent teeth. *J Dent* 2000;28:153-161.
 67. de Souza Costa CA, Hebling J, Hanks CT. Current status of pulp capping with dentin adhesive systems: A review. *Dent Mat* 2000;16:188-197.
 68. Costa CAS, Mesas AN, Hebling J. Pulp response to direct pulp capping with an adhesive. *Am J Dent* 2000;13:81-87.
 69. Inoue H, Muneyuki H, Izumi T, Taguchi K, Nishigawa Y, Watanabe K, Ohkawa Y, Tamura N. Electron microscopic study on nerve terminals during dentin bridge formation after pulpotomy in dog teeth. *J Endod* 1997;23:569-571.
 70. Nakamura M, Inoue T, Shimono M. Immunohistochemical study of dental pulp applied with 4-META/MMA-TBB adhesive resin after pulpotomy. *J Biomed Mater Res* 2000;51:241-248.
 71. Tziafas D, Smith AJ, Lesot H. Designing new treatment strategies in vital pulp therapy. *J Dent* 2000;28:77-92.
 72. Smith AJ, Tobias RS, Murray PE. Transdental stimulation of reactionary dentinogenesis in ferrets by dentine matrix components. *J Dent* 2001;29:341-346.
 73. Imazato S, Torii Y, Takatsuka T, Inoue K, Ebi N, Ebisu S. Bactericidal effect of dentin primer containing antibacterial monomer methacryloyloxydodecylpyridinium bromide (MDPB) against bacteria in human carious dentin. *J Oral Rehabil* 2001;28:314-319.
 74. Pereira JC, Segala AD, Souza Costa CA. Human pulpal response to direct pulp capping with an adhesive system. *Am J Dent* 2000;13:139-147.
 75. Christensen GJ. The need for caries-preventive restorative materials. *J Am Dent Assoc* 2000;131:1347-1349.